

# THORACIC SURGERY EMERGENCIES

Jason Ali  
Thoracic Surgery SpR

# THORACIC SURGERY EMERGENCIES

- ⦿ Mostly related to chest trauma
- ⦿ Can be divided into:
  - Life threatening problems
  - Potentially life-threatening problems

# LIFE-THREATENING PROBLEMS

- ⦿ Should be identified and managed in the 'primary survey'
- ⦿ Always approach patients in a systematic manner: 'ABCDE'
- ⦿ 'ATOM FC'

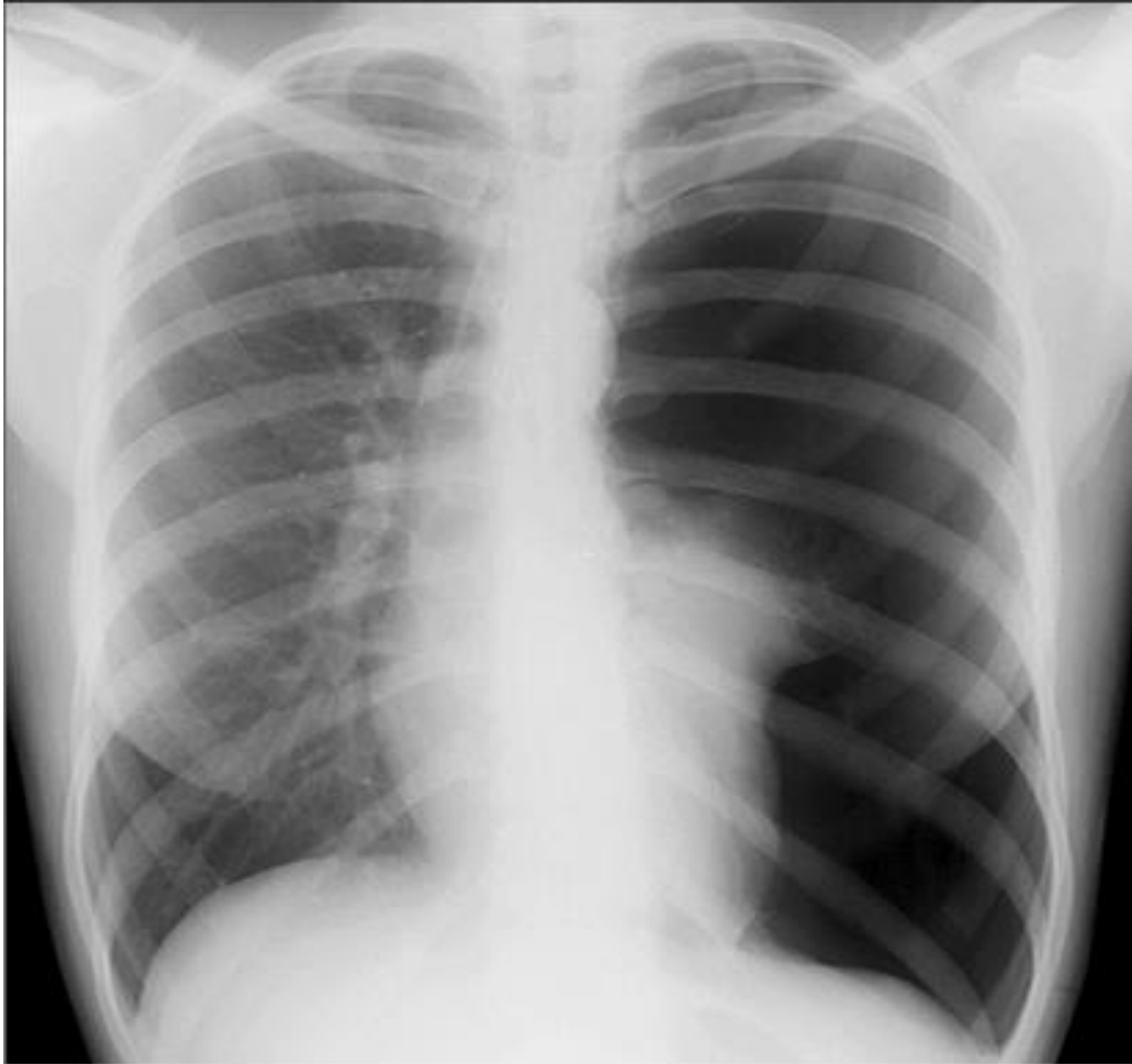# 1. AIRWAY OBSTRUCTION

- ⦿ How do you assess for airway obstruction?
  - Look
  - Listen
  - Feel
  
- ⦿ Scenarios in which airway obstruction may occur:
  - Maxillofacial trauma
  - Neck trauma
  - Laryngeal trauma

# 1. AIRWAY OBSTRUCTION

- What are the options to secure an airway?
  - Chin lift / jaw thrust
  - Oropharyngeal / nasopharyngeal airways
  - Endotracheal intubation
  
  - Needle cricothyroidotomy
  - Surgical tracheostomy

2.

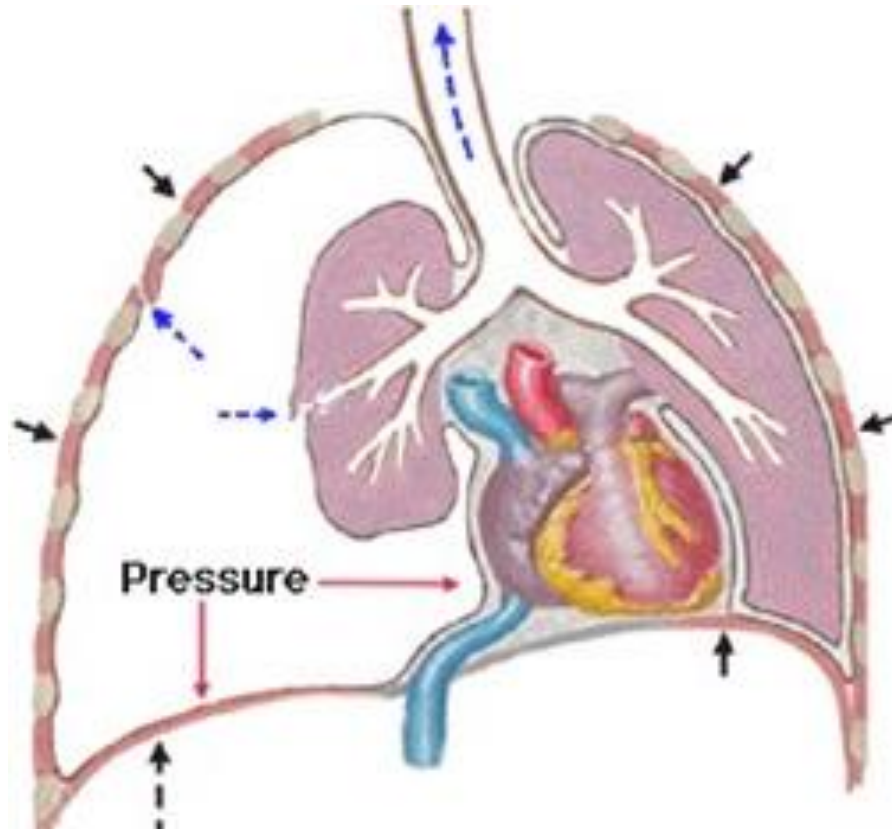


## 2. TENSION PNEUMOTHORAX

- ⊙ A clinical diagnosis
- ⊙ Clinical presentation?
  - Chest pain
  - SOB
  - Tachycardia
  - Hypotension
  - Tracheal deviation
  - Hyperresonance
  - Decreased breath sounds
  - Neck vein distension

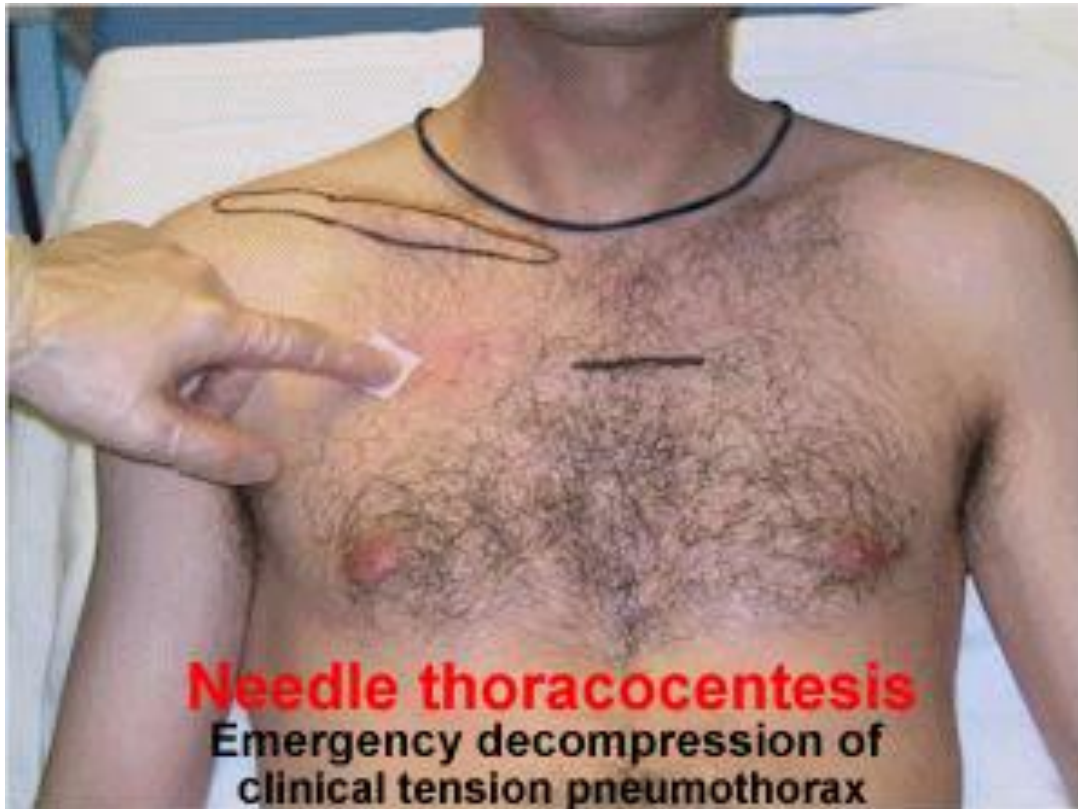
# 2 TENSION PNEUMOTHORAX

- Why is it life threatening?

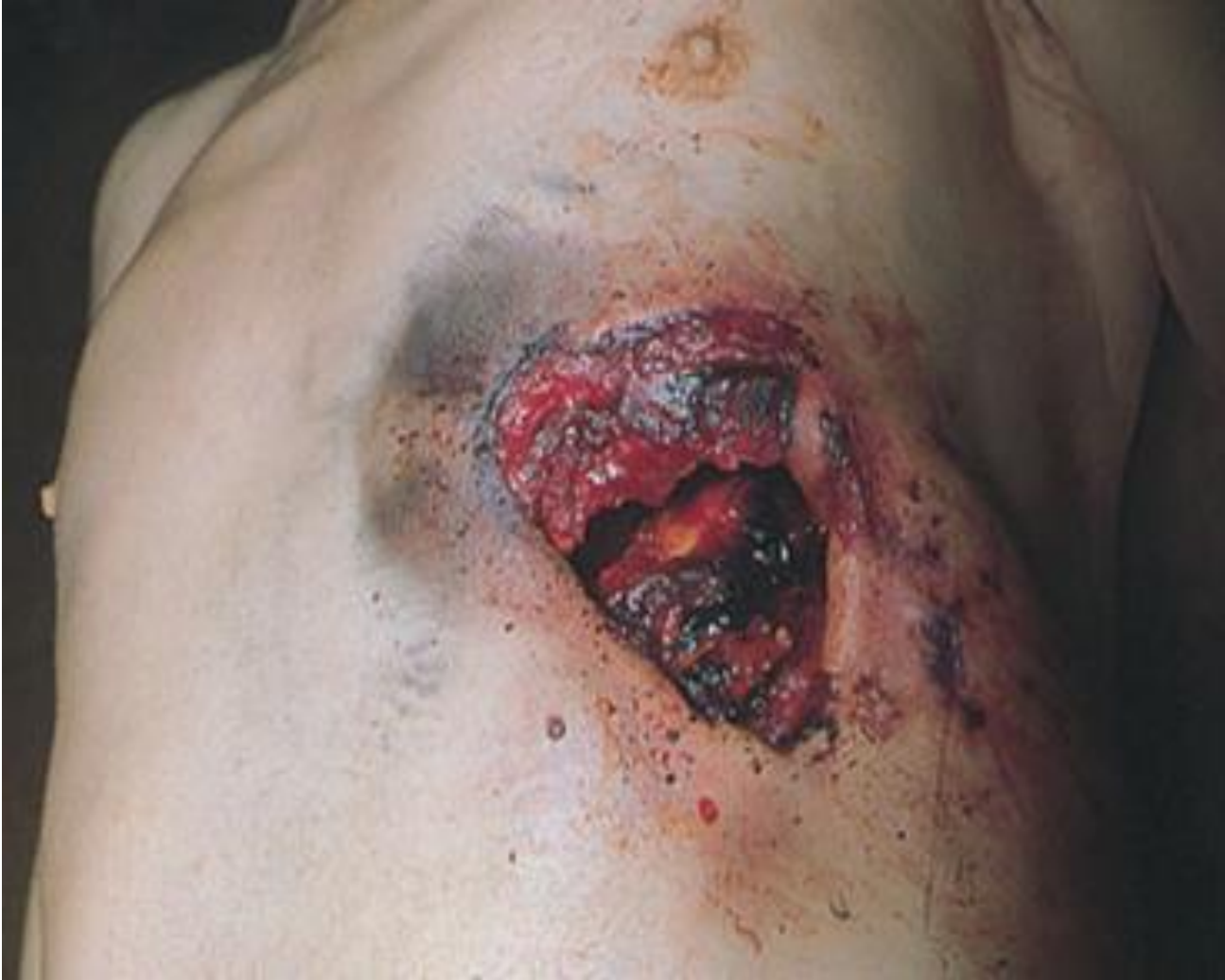

## 2. TENSION PNEUMOTHORAX

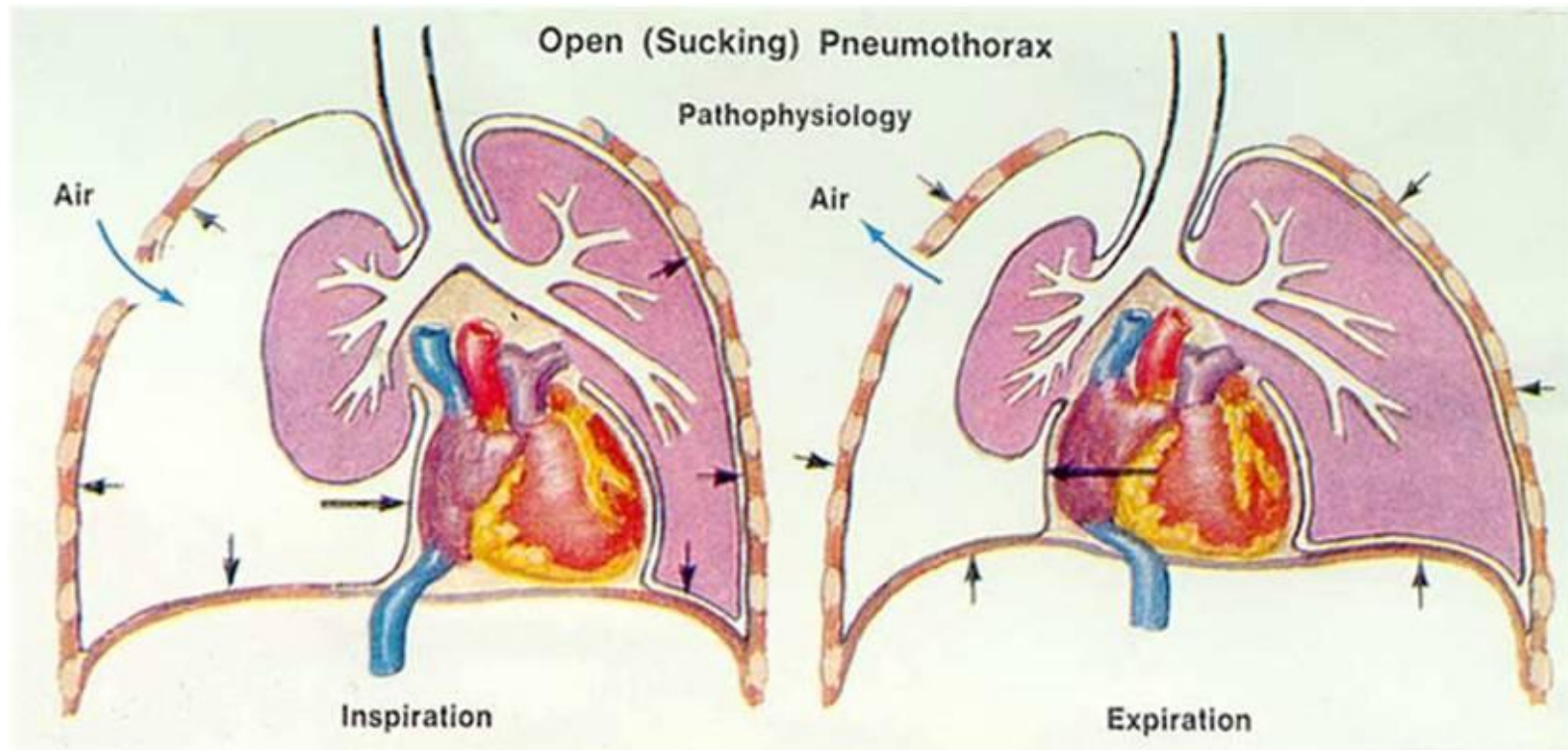
- Management



3.

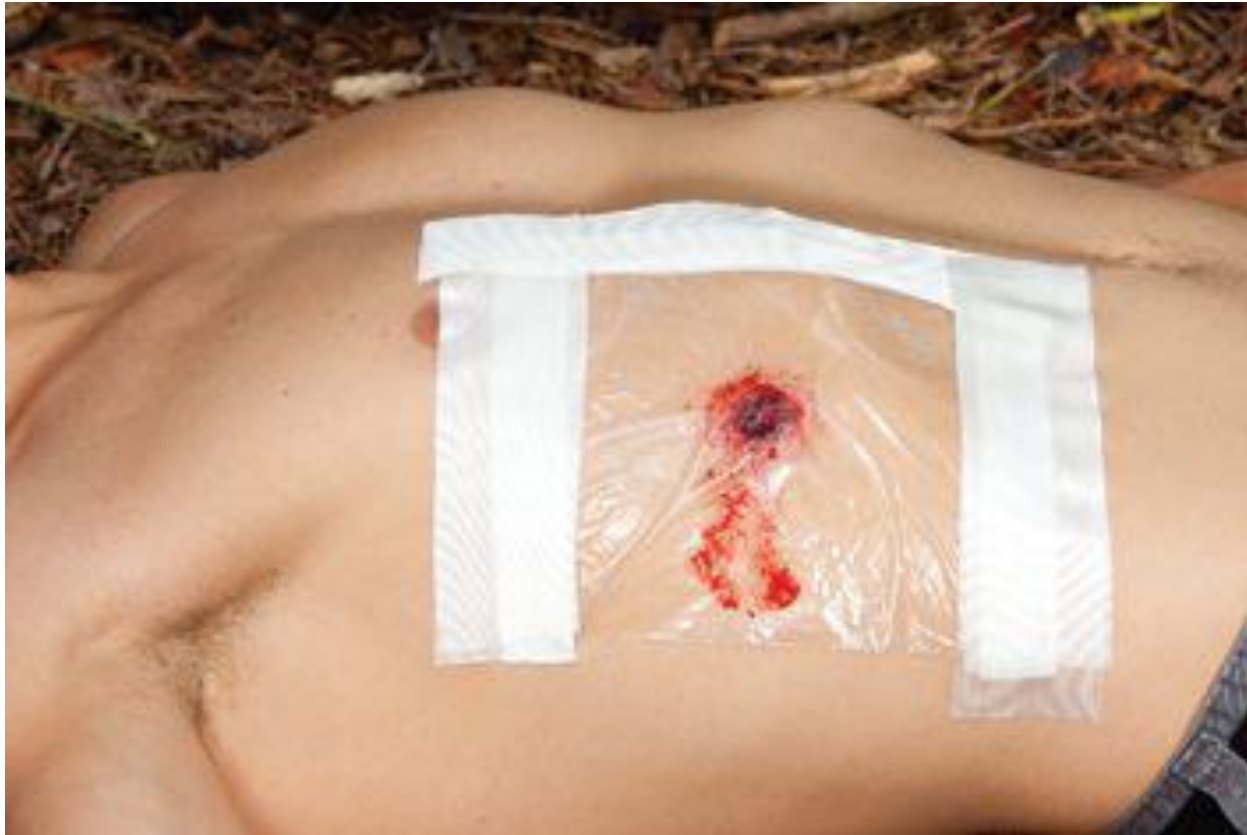

# 3. OPEN PNEUMOTHORAX

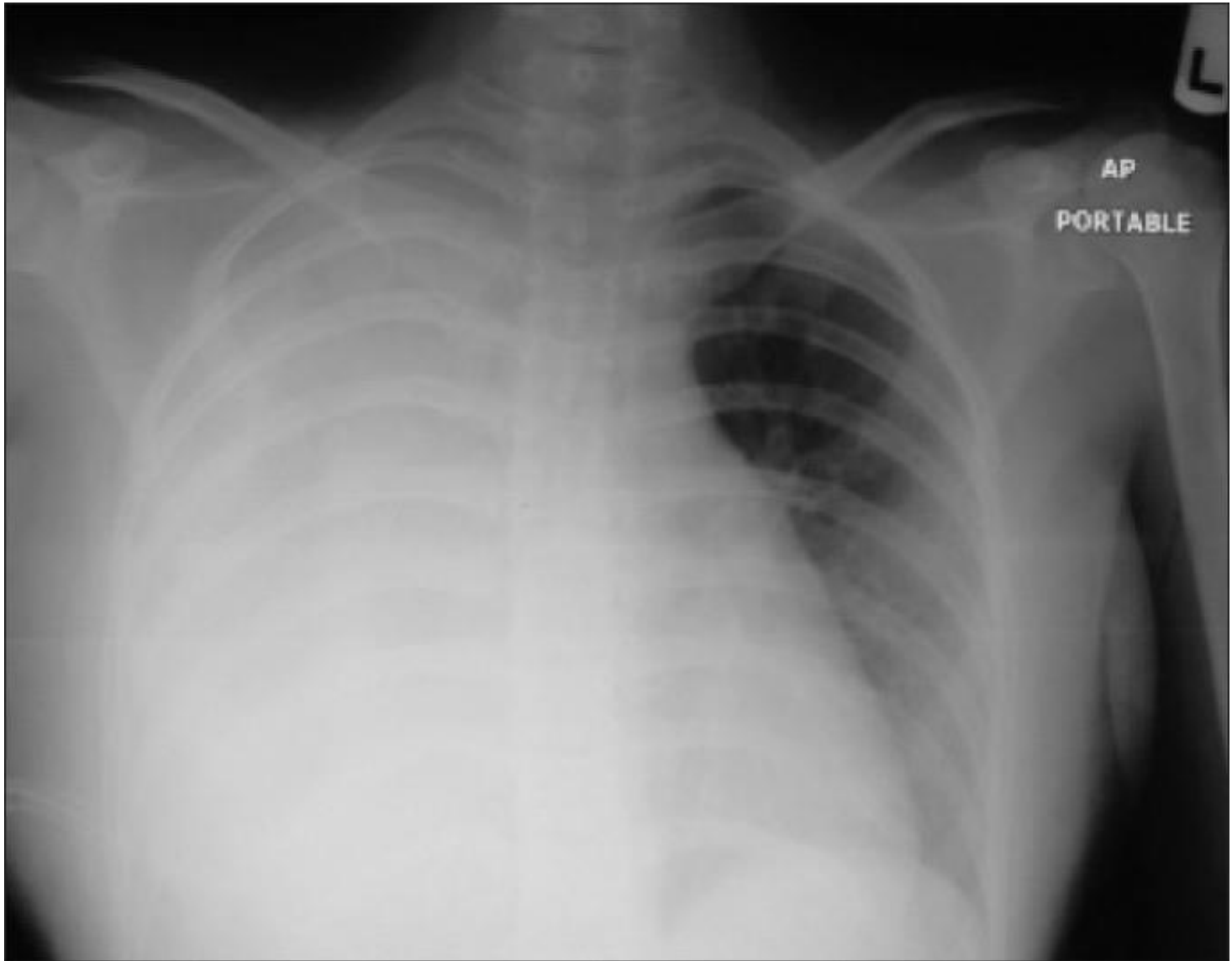

# 3. OPEN PNEUMOTHORAX

- Management?



4.



# 4. MASSIVE HAEMOTHORAX

## ○ Clinical assessment

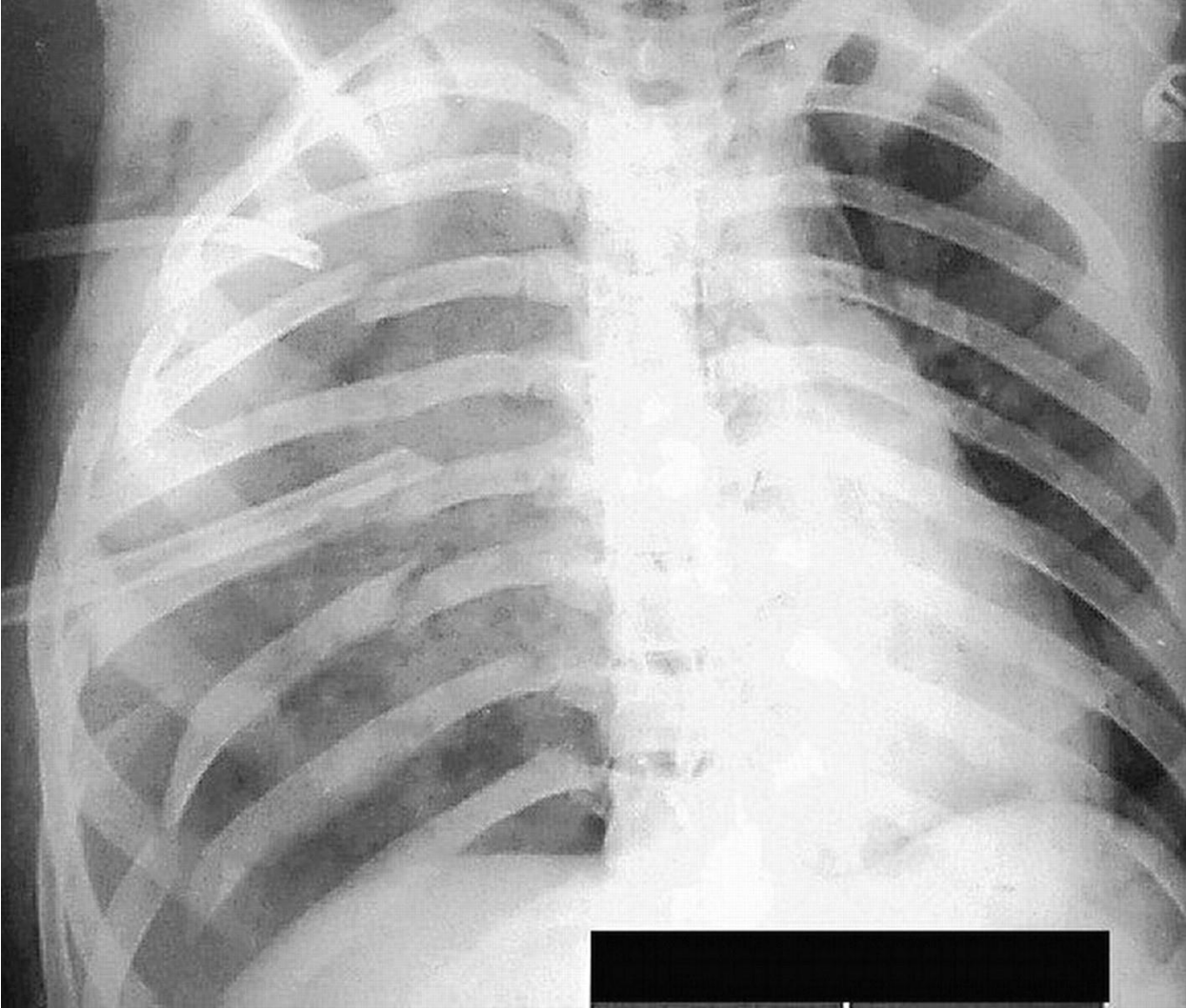
- A
  
- B
  - Hypoxia / tachypnoea
  - Decreased breath sounds
  - Dull percussion note
  - +/- mediastinal shift
  
- C
  - Hypotension
  - Tachycardia

# 4. MASSIVE HAEMOTHORAX

## ◉ Management?

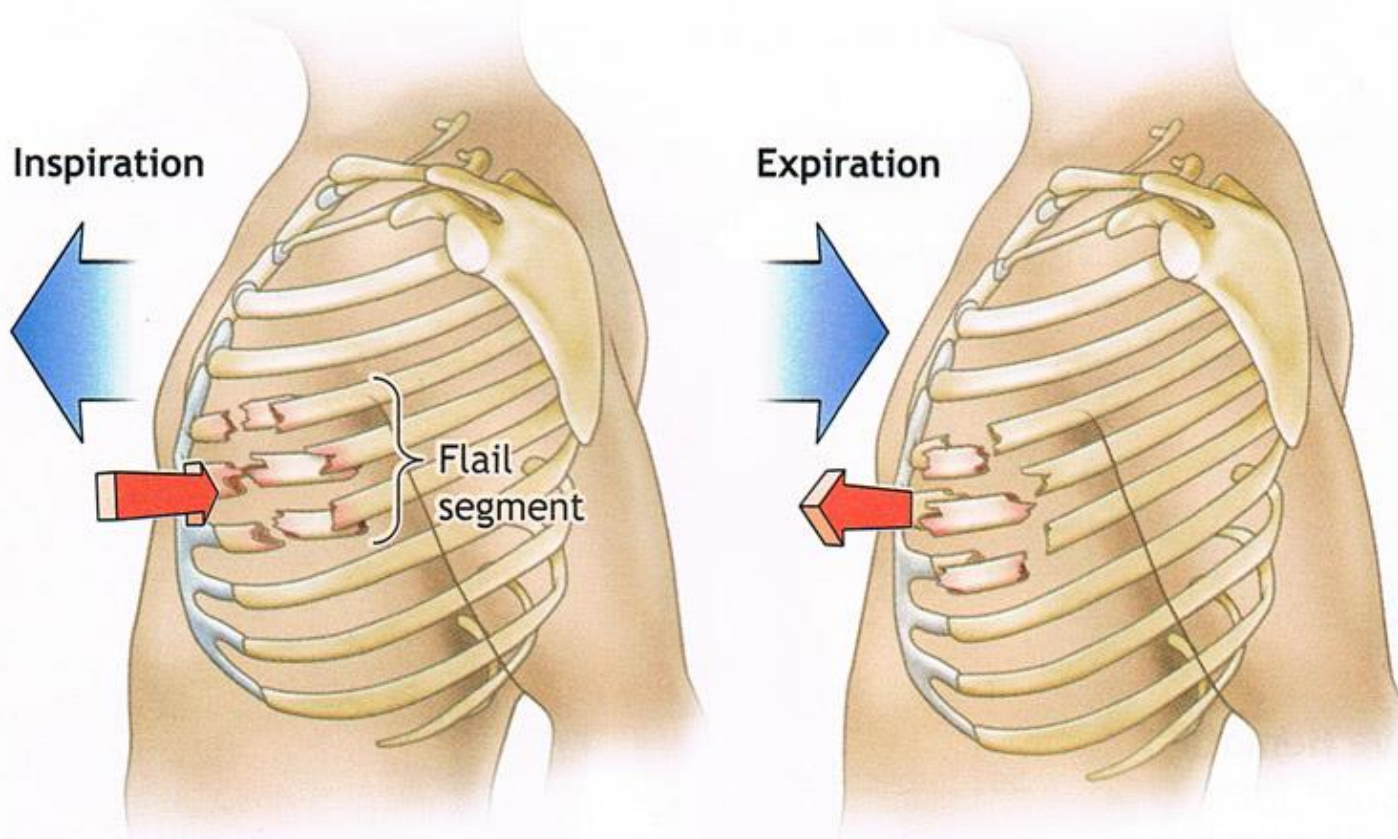
- A/B
  - Oxygen
  
- C
  - Large bore cannulae
  - Bloods - which?
  - Fluids - which?
  - Drain (+/- autotransfusion)
  
- +/- Prepare for theatre

5.



# 5. FLAIL CHEST

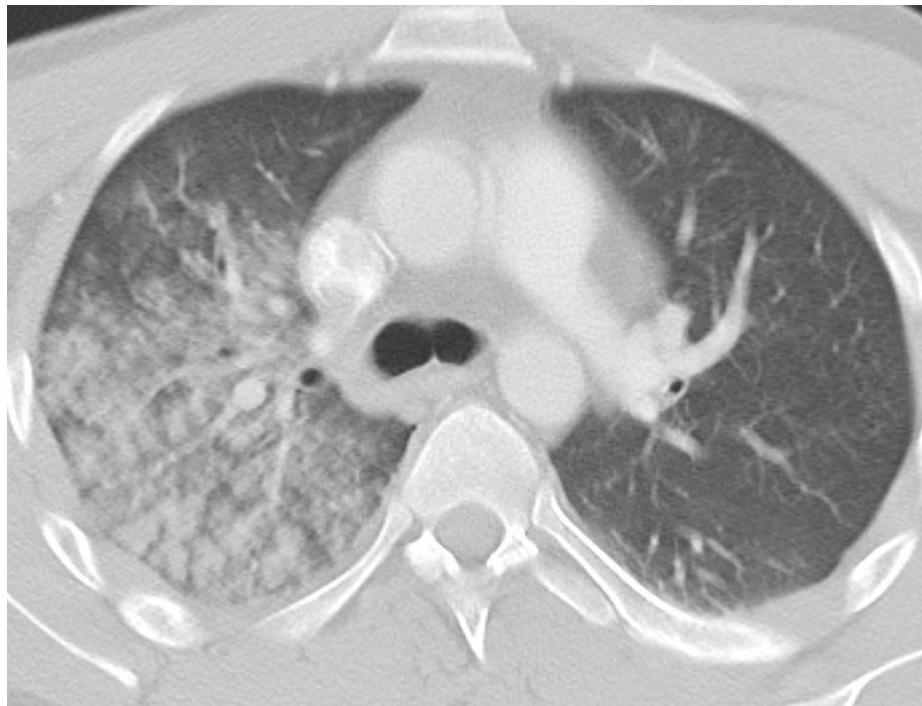
- Clinical sign?



## 5. FLAIL CHEST

### ◉ Why is this life-threatening?

- Underlying lung contusion
- Restricted chest wall movement due to pain



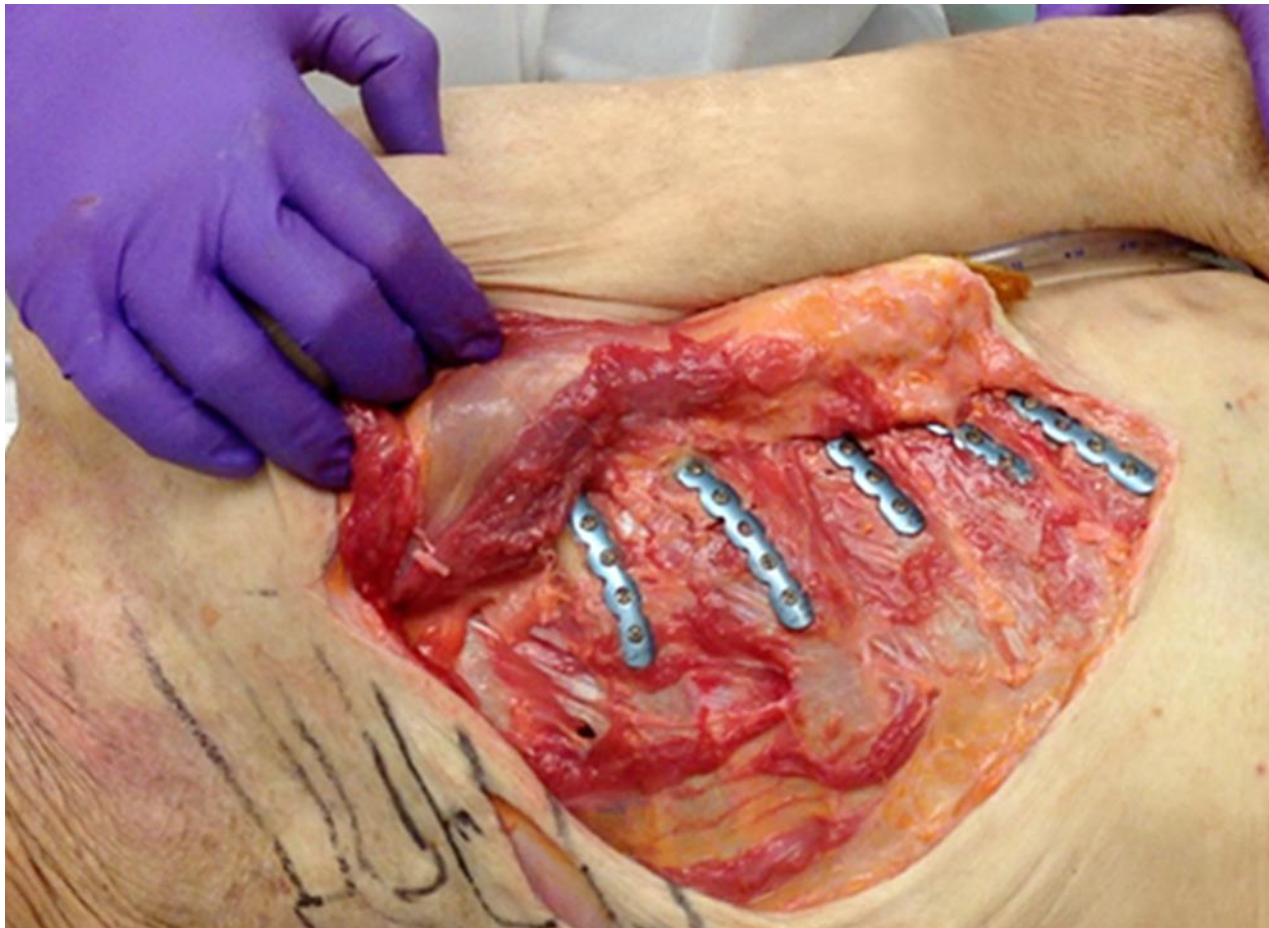
# 5. FLAIL CHEST

## ◉ Management

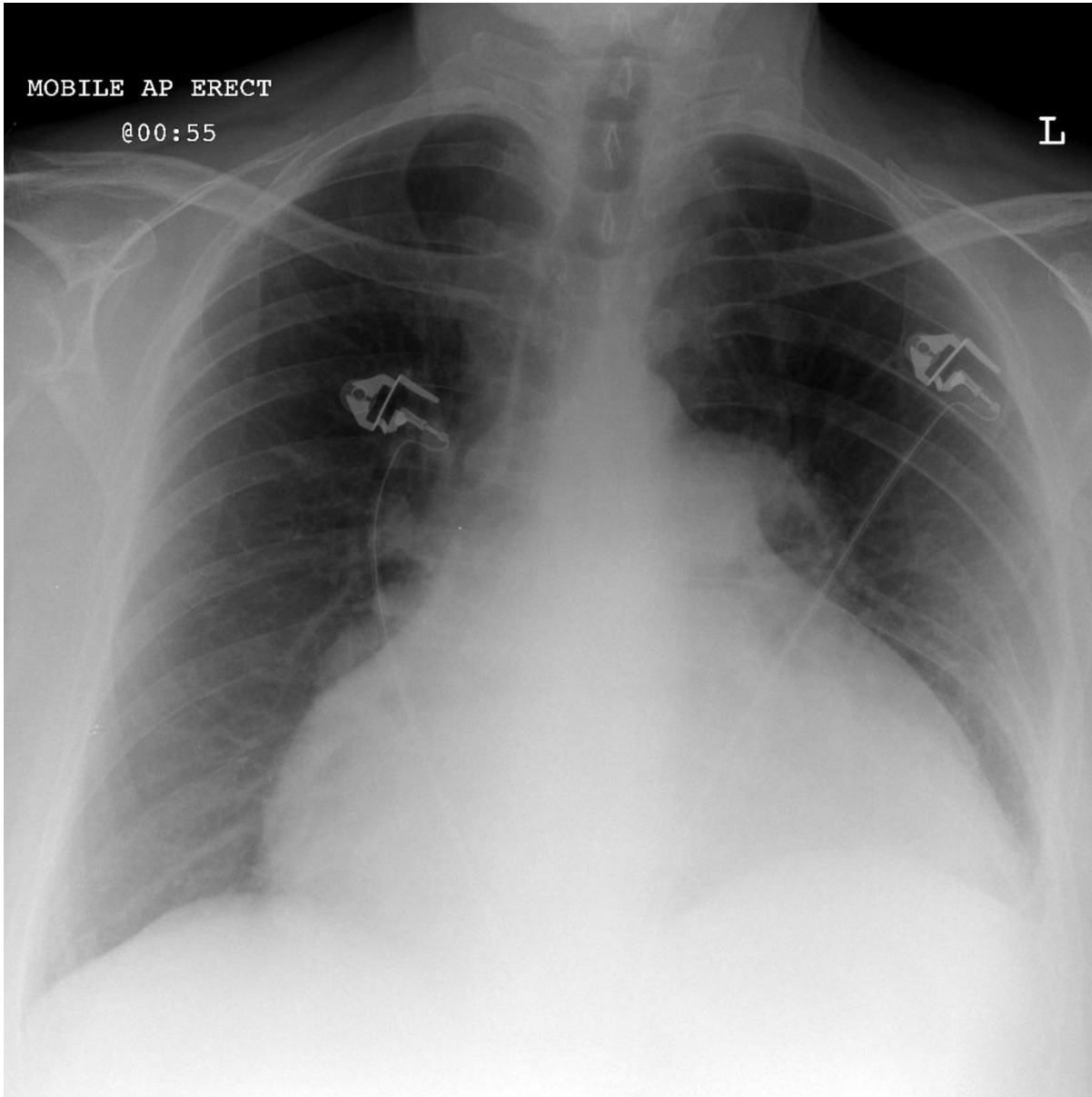
- ANALGESIA
- Chest physiotherapy
- Cautious fluid management
  
- May require invasive ventilation

# 5. FLAIL CHEST

- Rib fixation



6.



# 6. CARDIAC TAMPONADE

## ○ Clinical presentation?

- Becks triad
  - Increased JVP
  - Hypotension
  - Muffled heart sounds
- Kussmauls sign
  - Rise in JVP with inspiration
- Pulsus paradoxus
  - Fall in systolic  $>10\text{mmHg}$  with inspiration

# 6. CARDIAC TAMPONADE

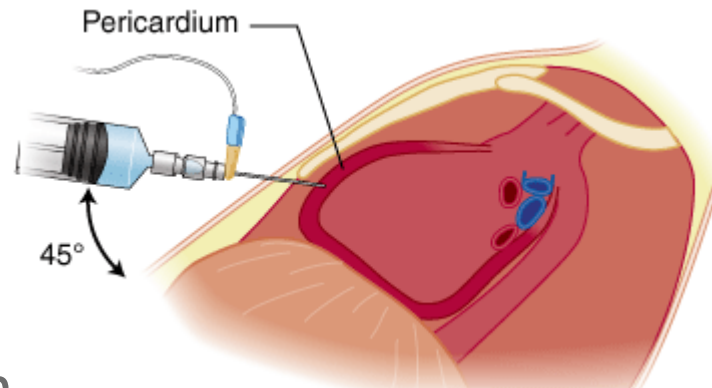
## ⦿ Diagnosis?

- Echocardiogram 'FAST' scan
  - Effusion
  - Right ventricular diastolic dysfunction
  - Bowing of interventricular septum

# 6. CARDIAC TAMPONADE

## Management?

- Pericardiocentesis
- Pericardial drain insertion
- +/- surgical exploration



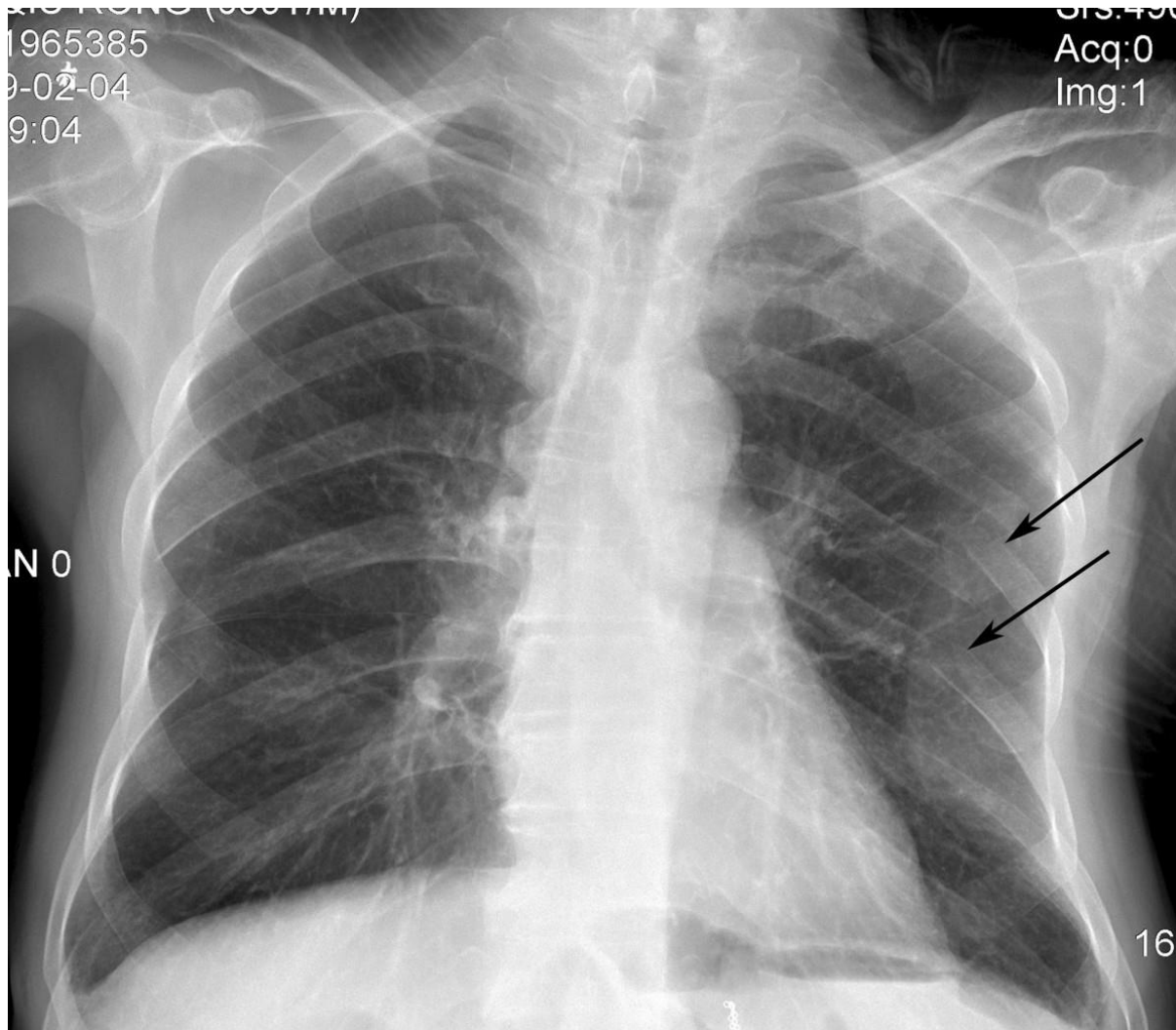
# POTENTIALLY LIFE-THREATENING PROBLEMS

- ◉ Simple pneumothorax
- ◉ Haemothorax
- ◉ Pulmonary contusion
- ◉ Tracheobronchial tree injury
- ◉ Blunt cardiac injury
- ◉ Traumatic aortic disruption
- ◉ Traumatic diaphragmatic injury
- ◉ Blunt oesophageal rupture

# COMMON THORACIC ADMISSIONS

- ⦿ Haemo/pneumothoraces
- ⦿ Rib / sternal fractures

# RIB FRACTURES



# MANAGEMENT

- ◉ ANALGESIA

- PCA
- EPIDURAL

- ◉ Chest physiotherapy - regular deep breathing and coughing is essential


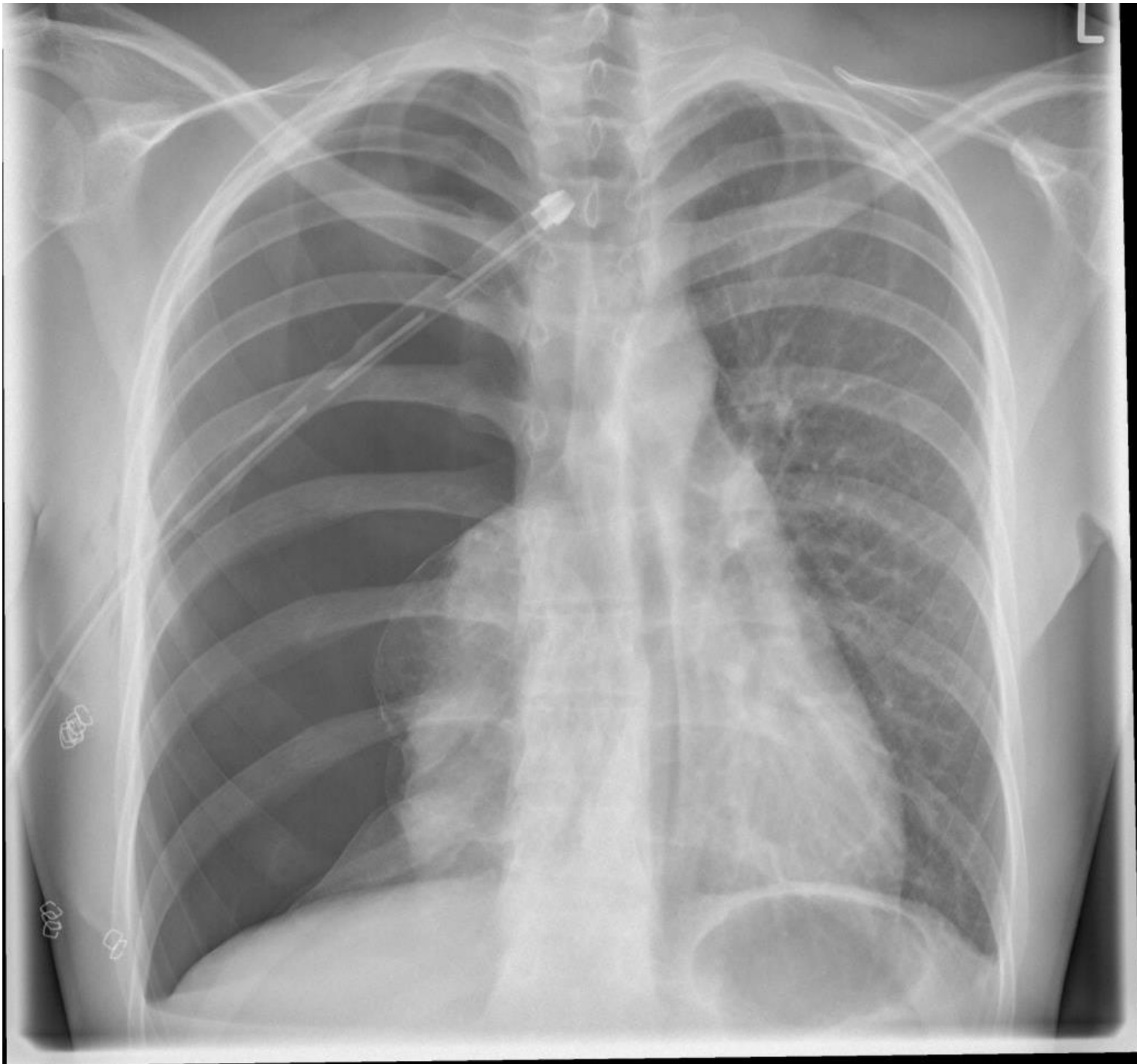
- ◉ Mobilisation

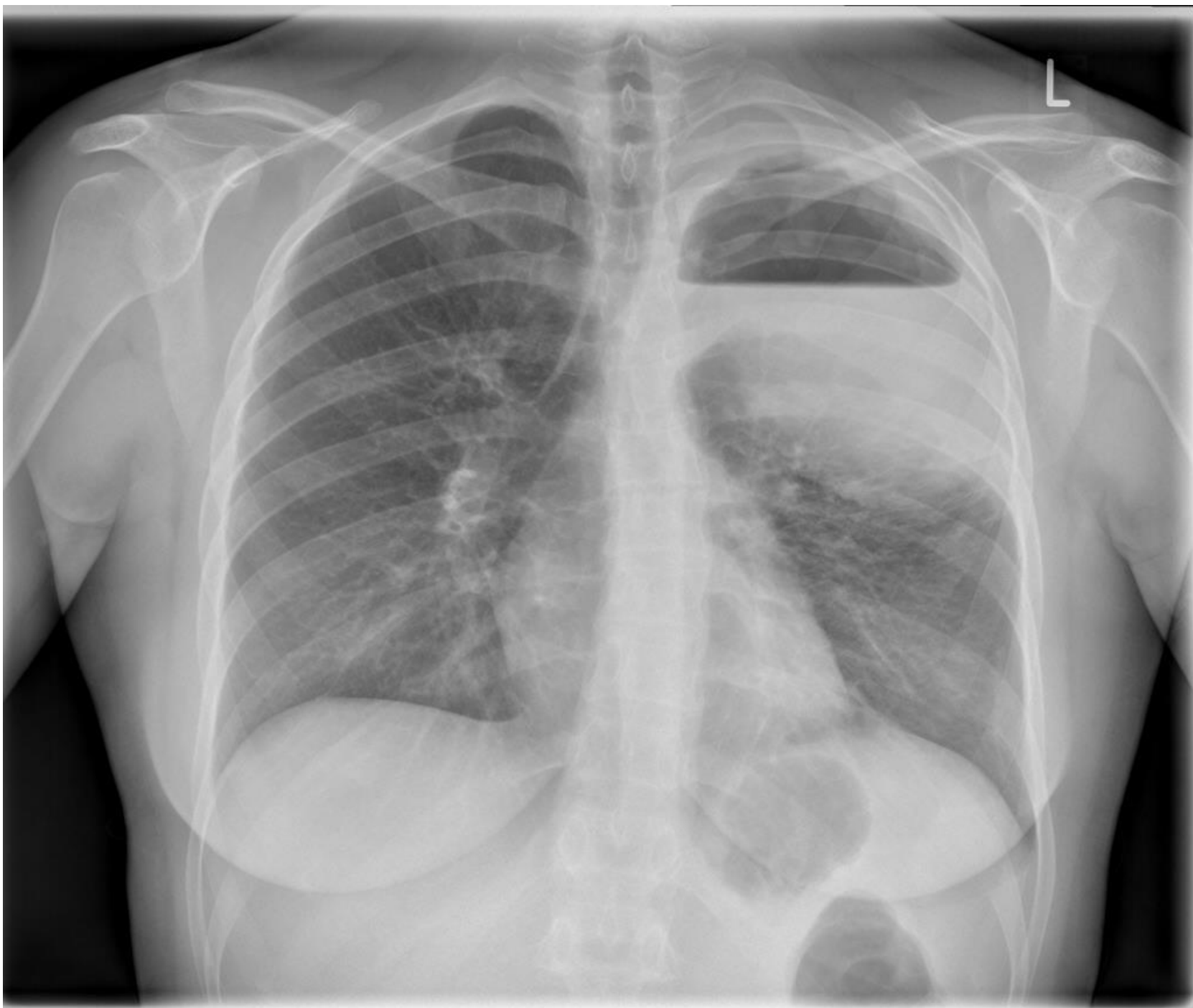
- ◉ Surgical fixation is rare

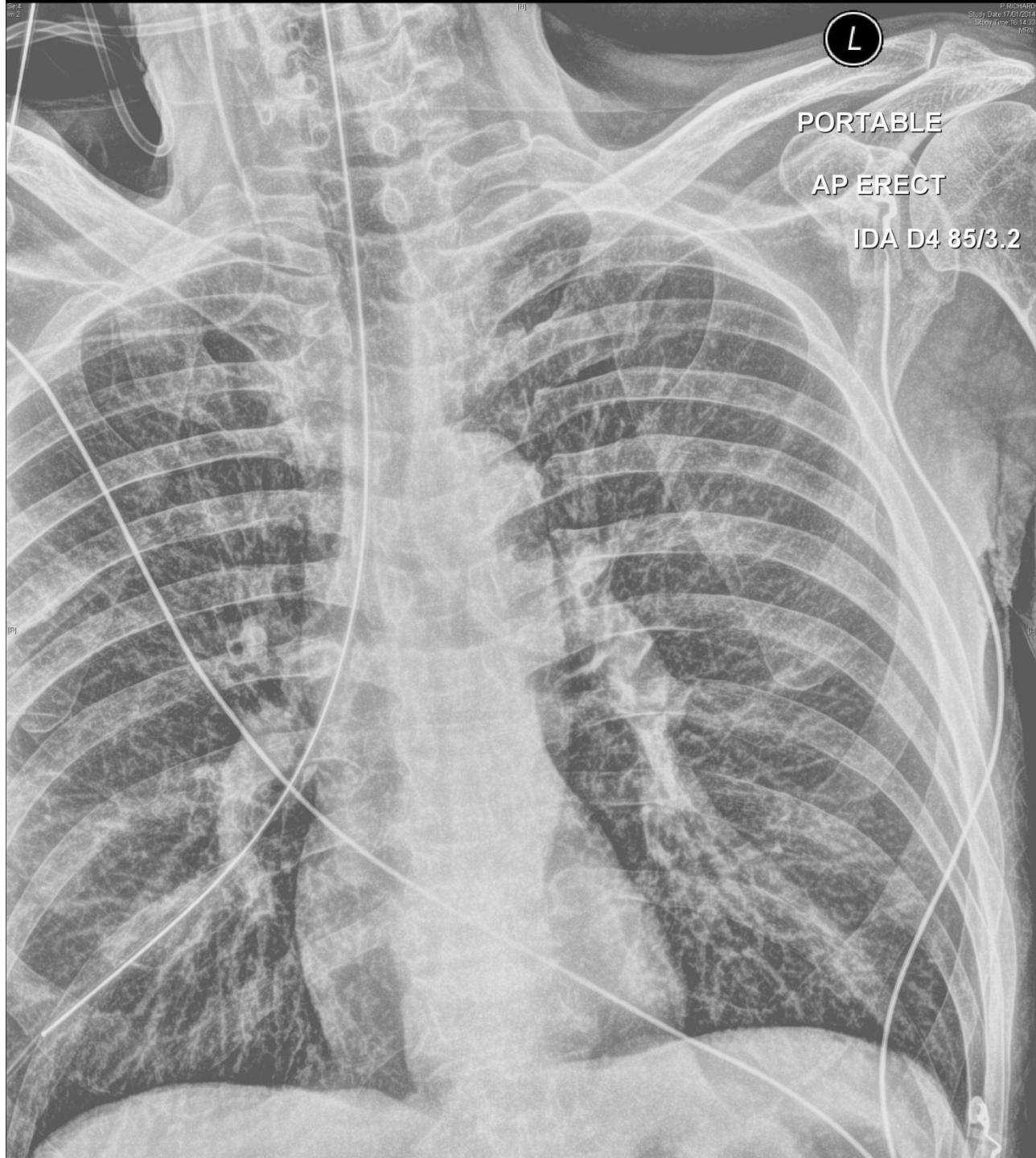# MANAGEMENT - STERNAL #

- ⦿ Cardiac monitoring
- ⦿ Cardiac enzymes
- ⦿ +/- urgent echo if arrhythmia/instability
- ⦿ Analgesia

# INTERESTING CXR







L

PORTABLE

AP ERECT

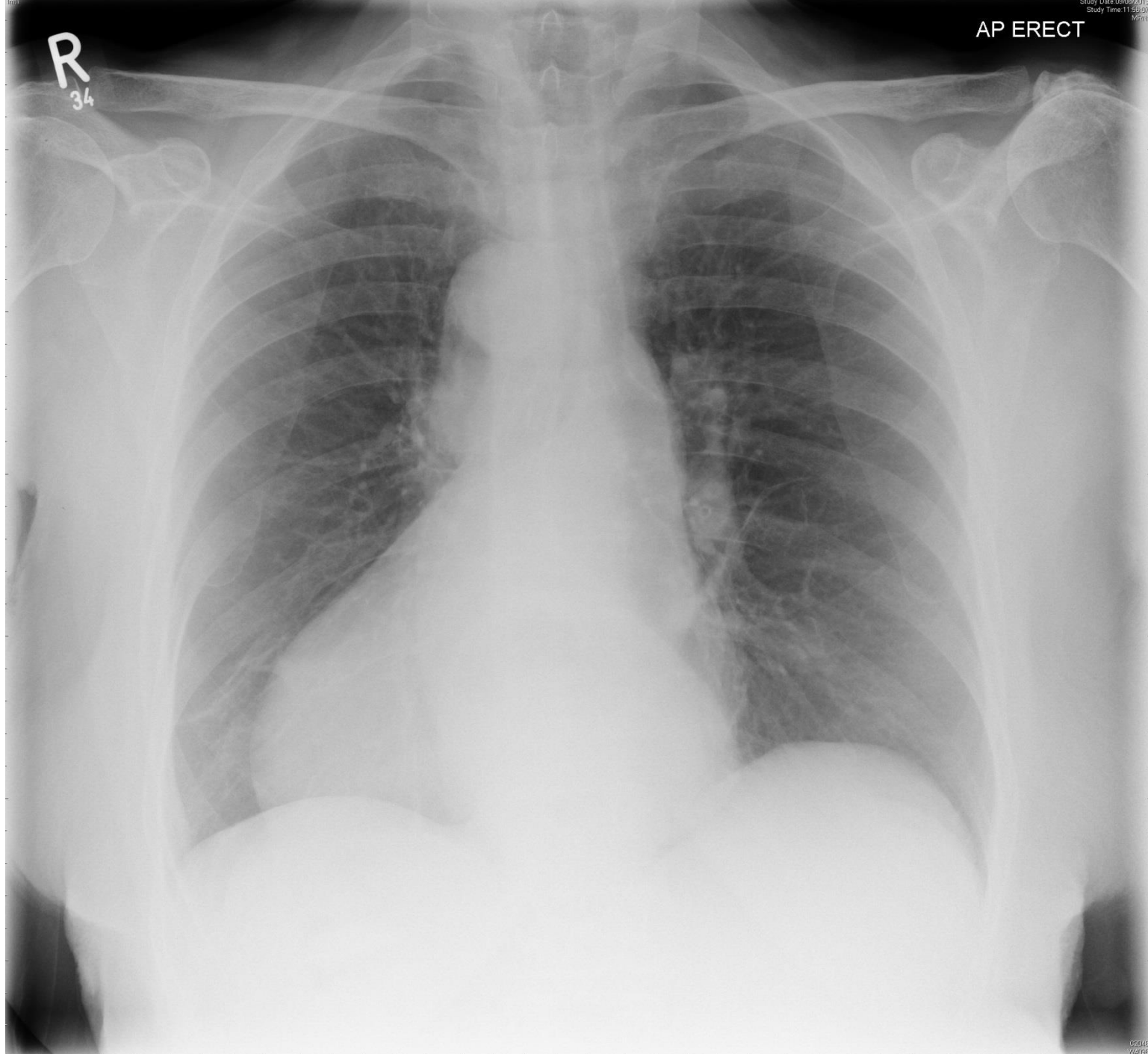
IDA D4 85/3.2

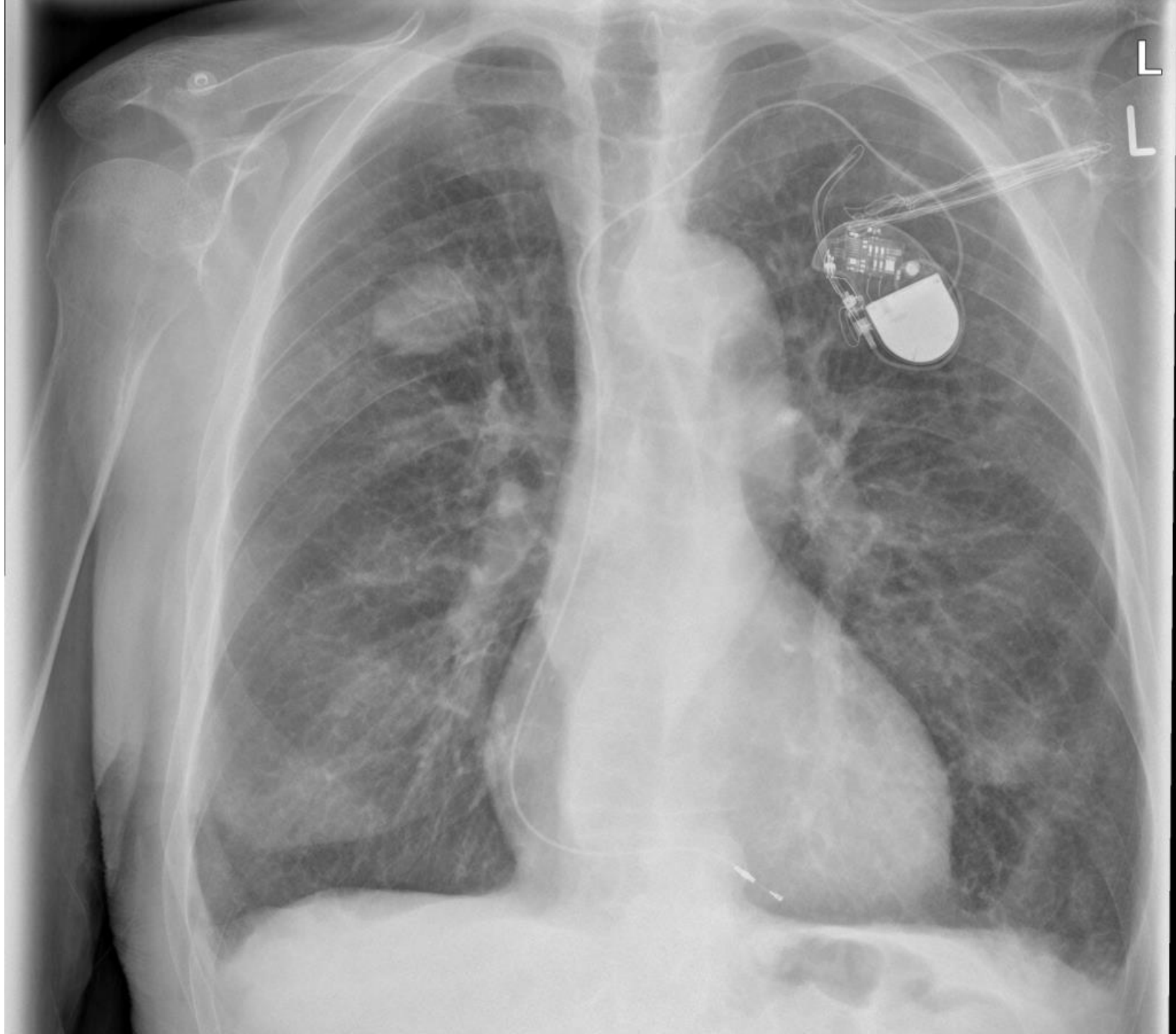
P. RICHARD  
Exp. Date: 11/01/2014  
Exp. Time: 14:55  
MPN

PI

AP ERECT

R  
34





# SUMMARY

- ⦿ Life threatening thoracic emergencies:
  - ⦿ A - Airway obstruction
  - ⦿ T - Tension pneumothorax
  - ⦿ O - Open pneumothorax
  - ⦿ M - Massive haemothorax
  - ⦿ F - Flail chest
  - ⦿ C - Cardiac tamponade