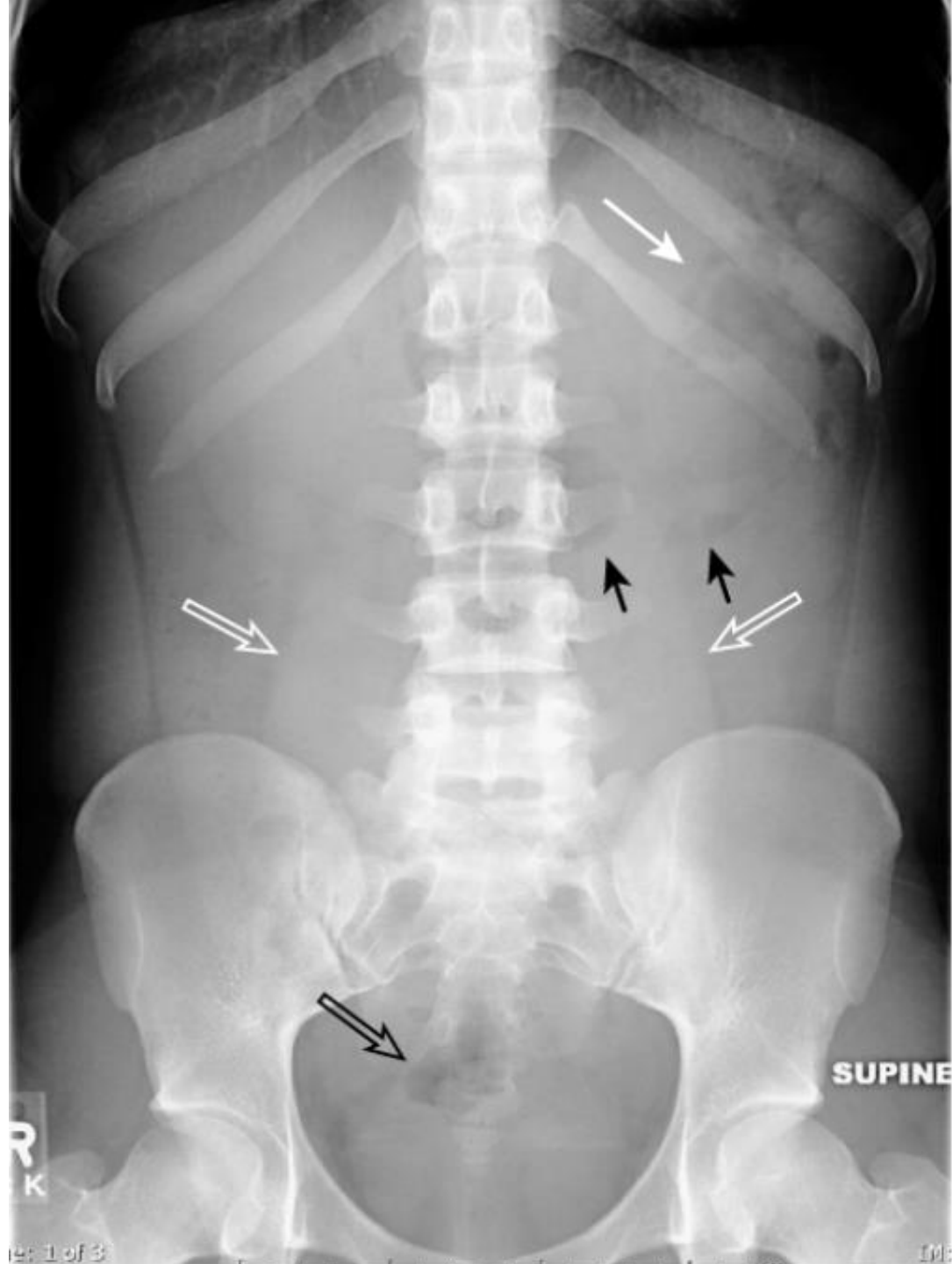

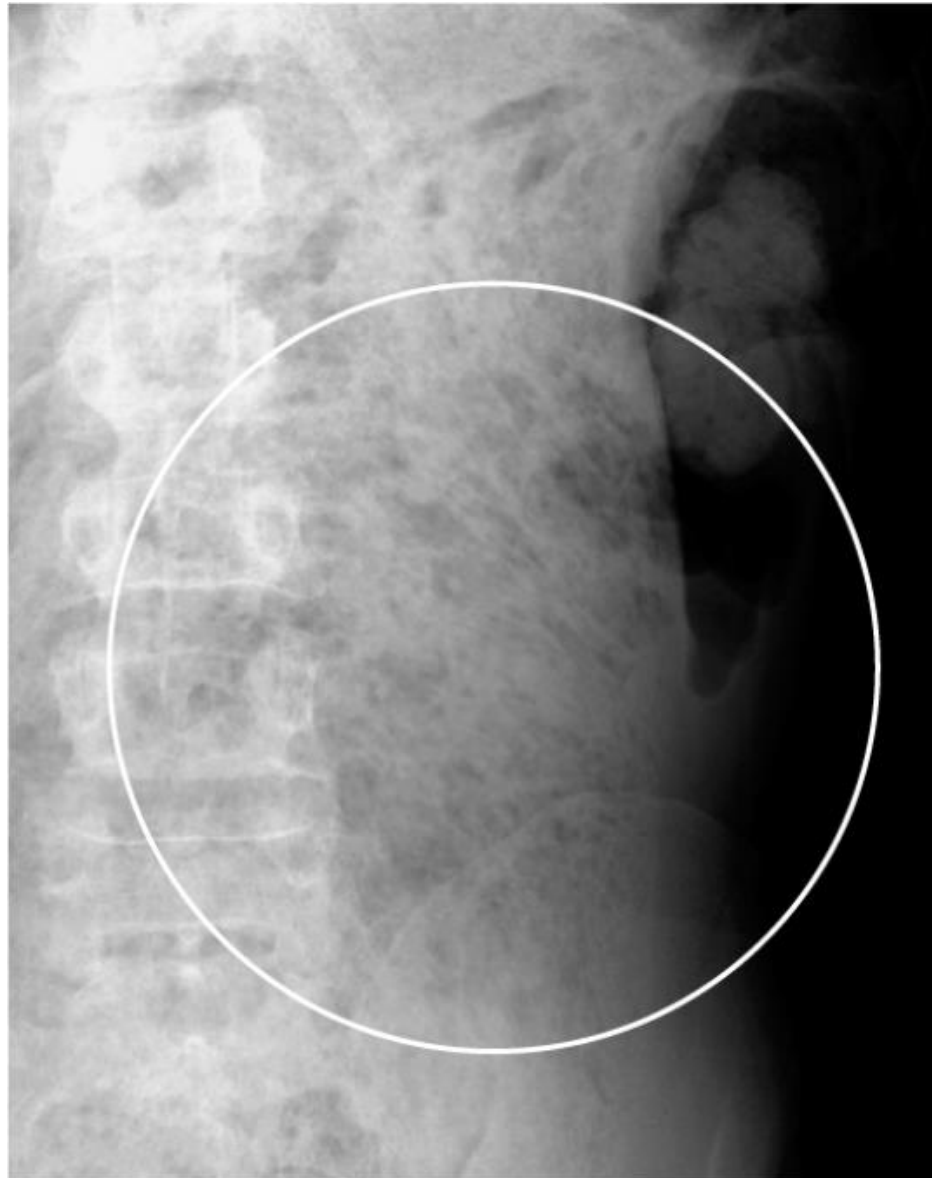Abdominal Radiographs

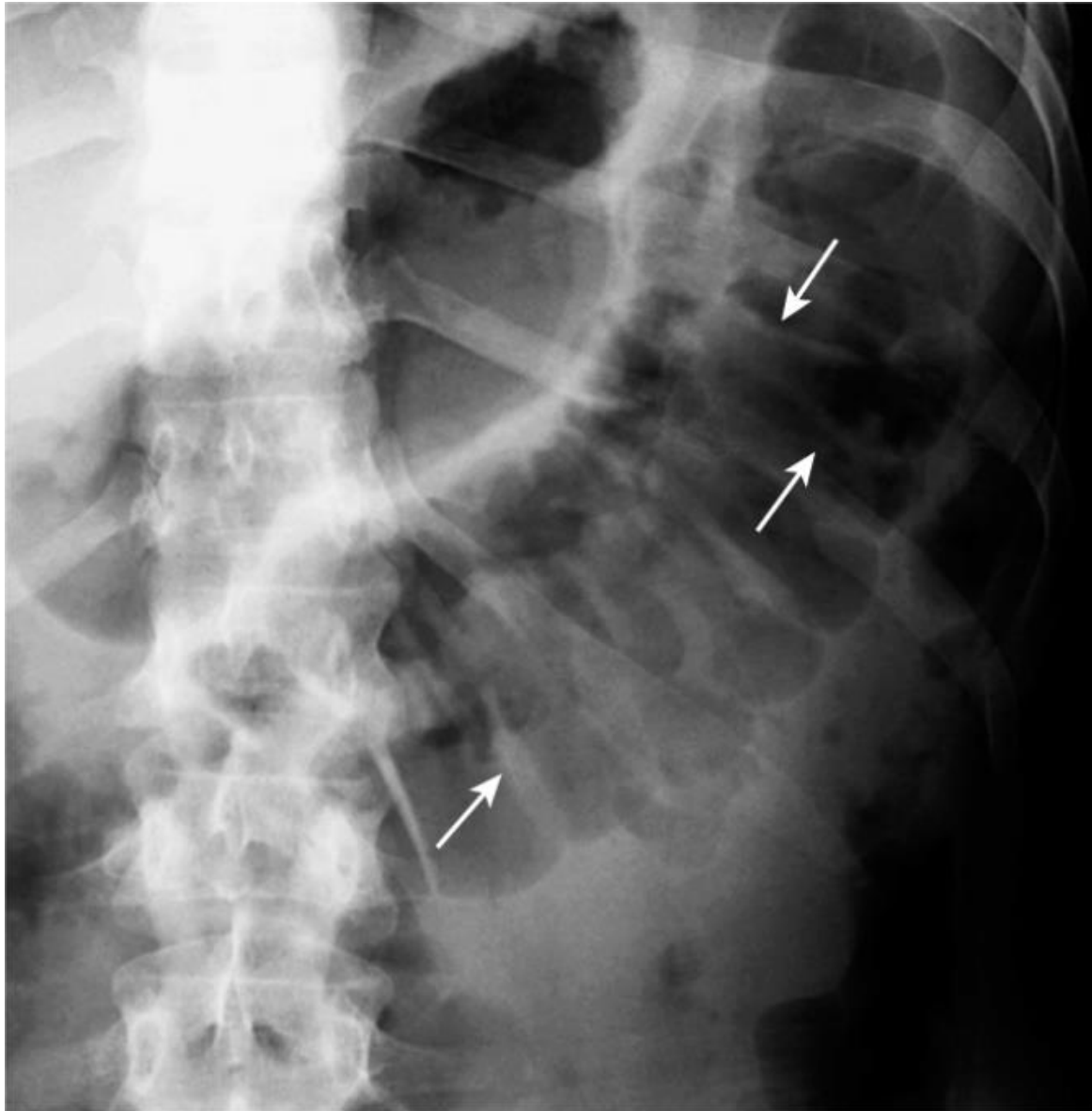J Ali

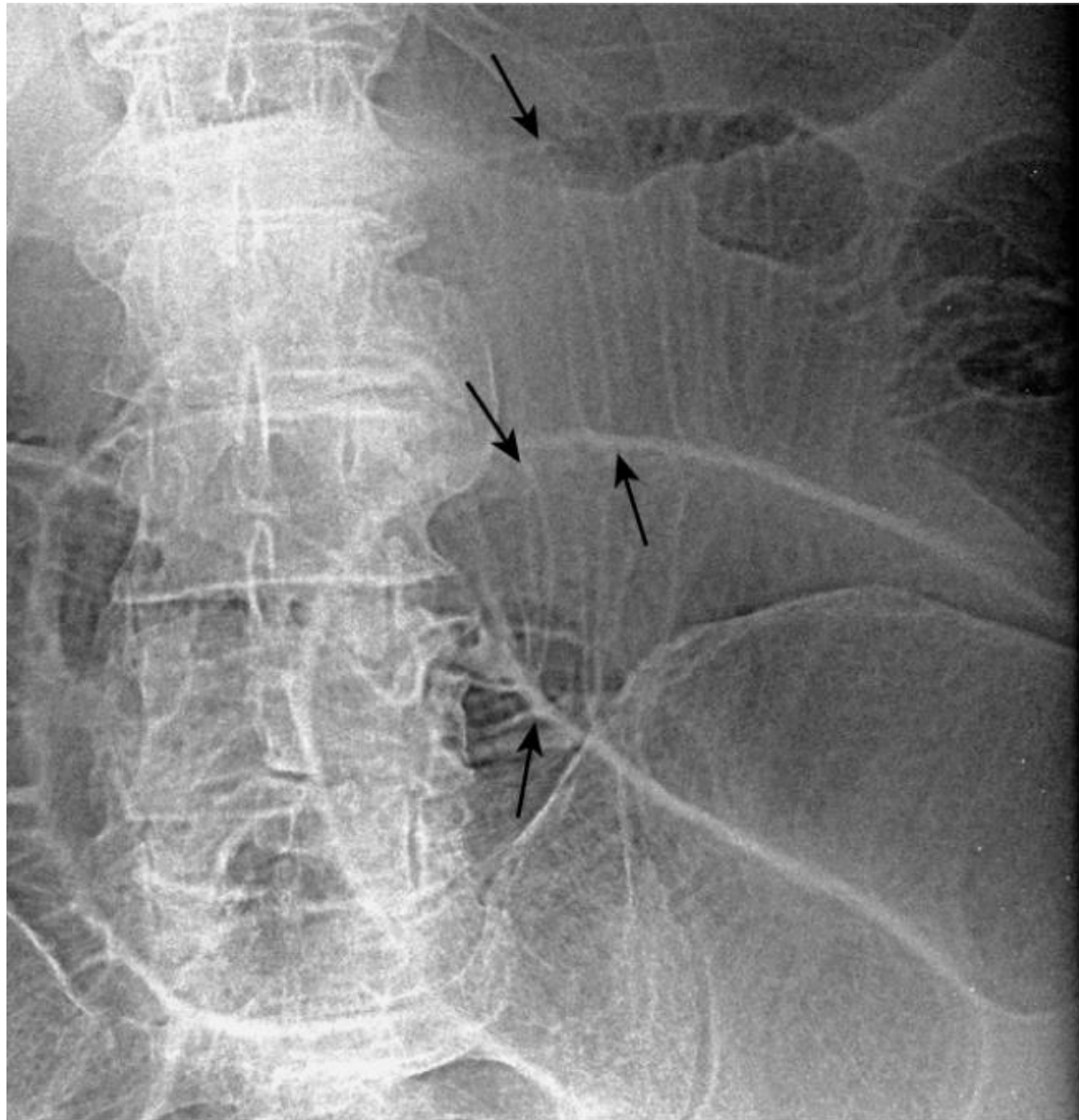
What to look for

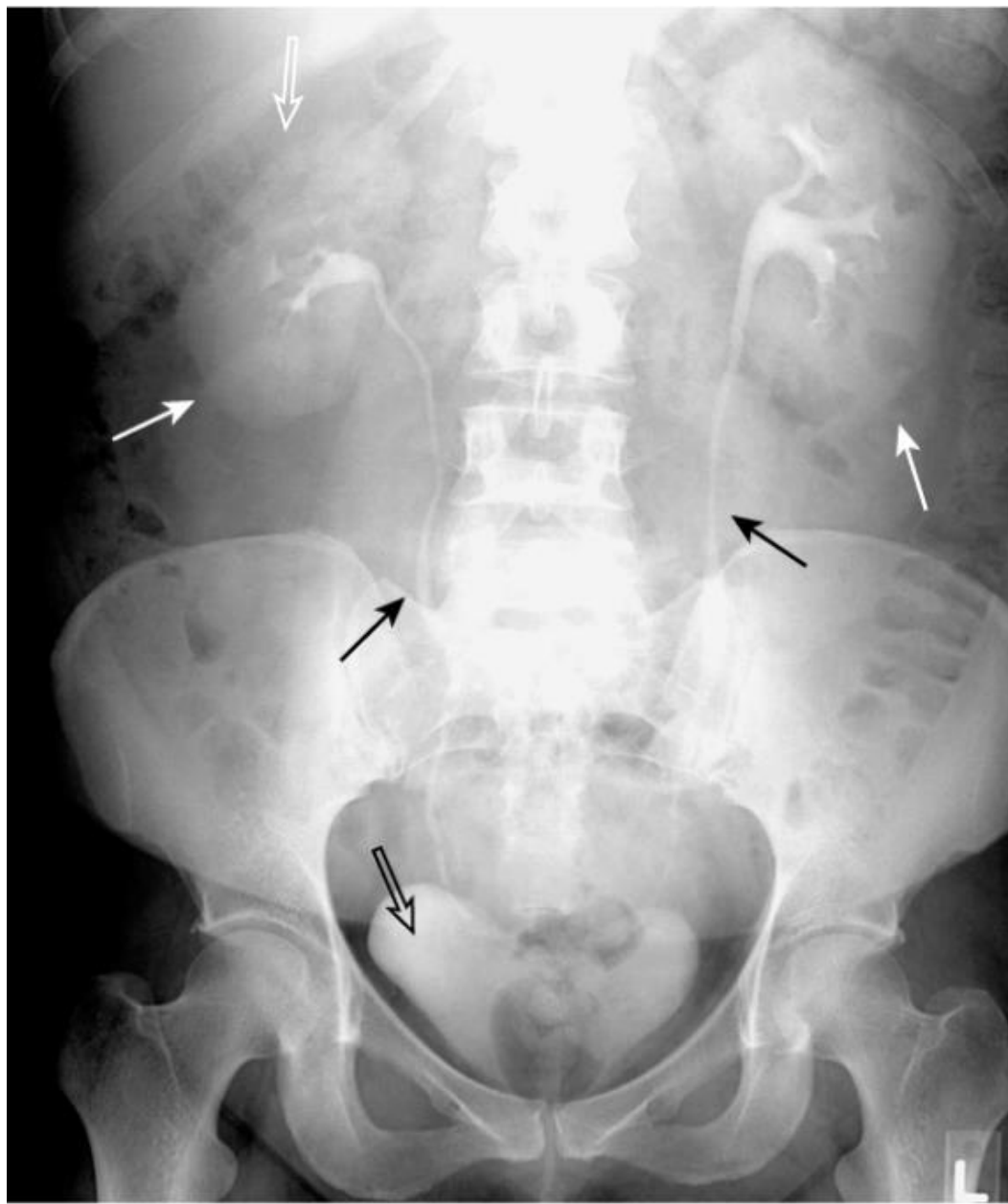- Overall gas pattern
 - Stomach
 - Rectum/sigmoid
 - Obstructed bowel
- ? Extraluminal air
- Abnormal calcifications
- Abnormal masses

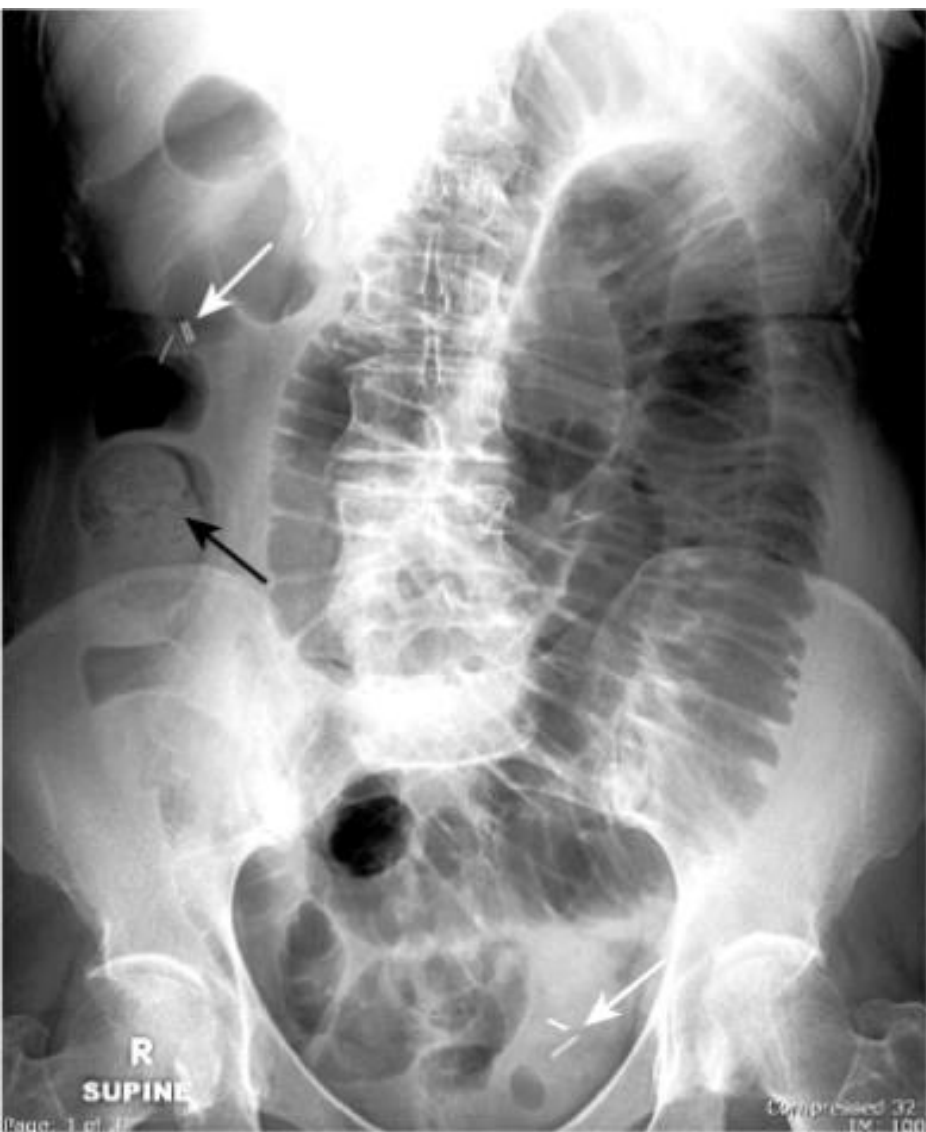



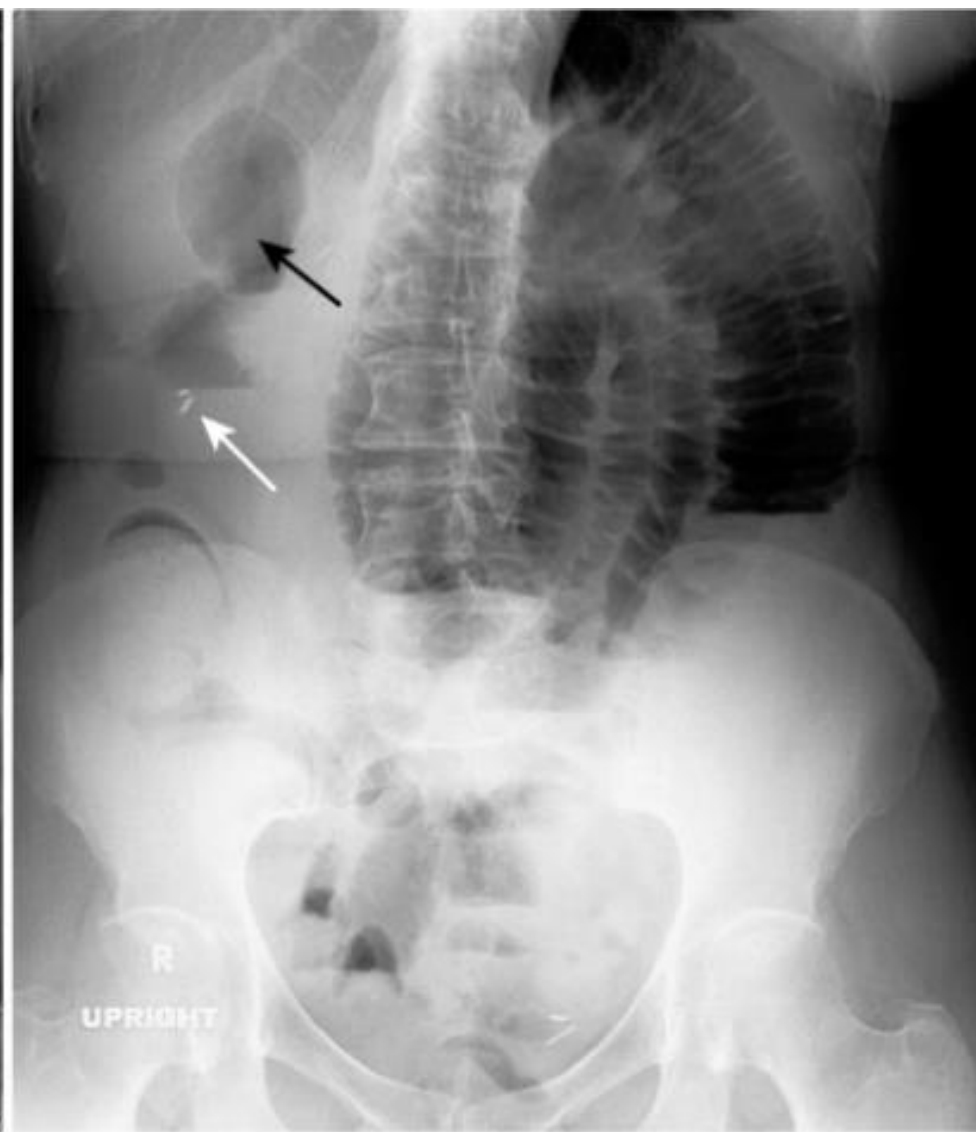





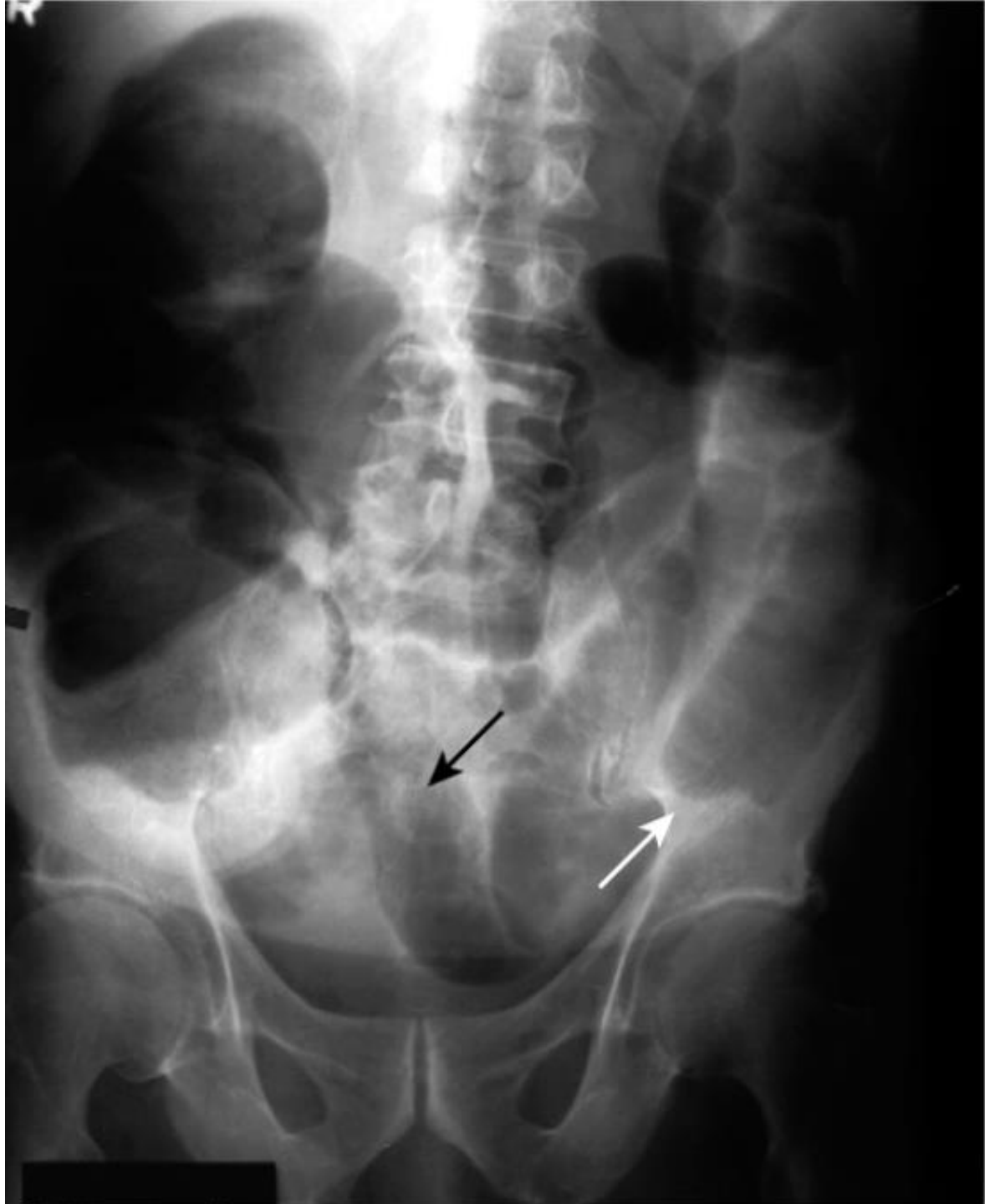
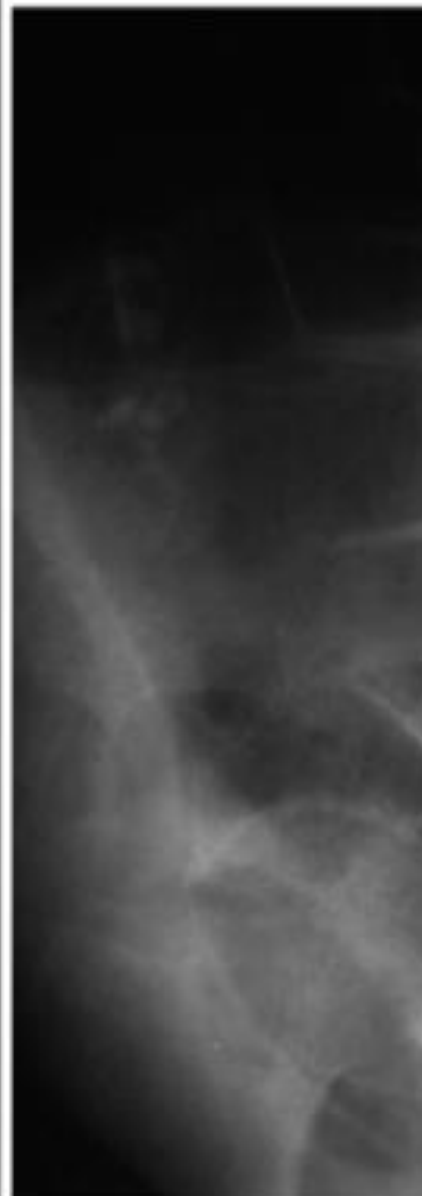
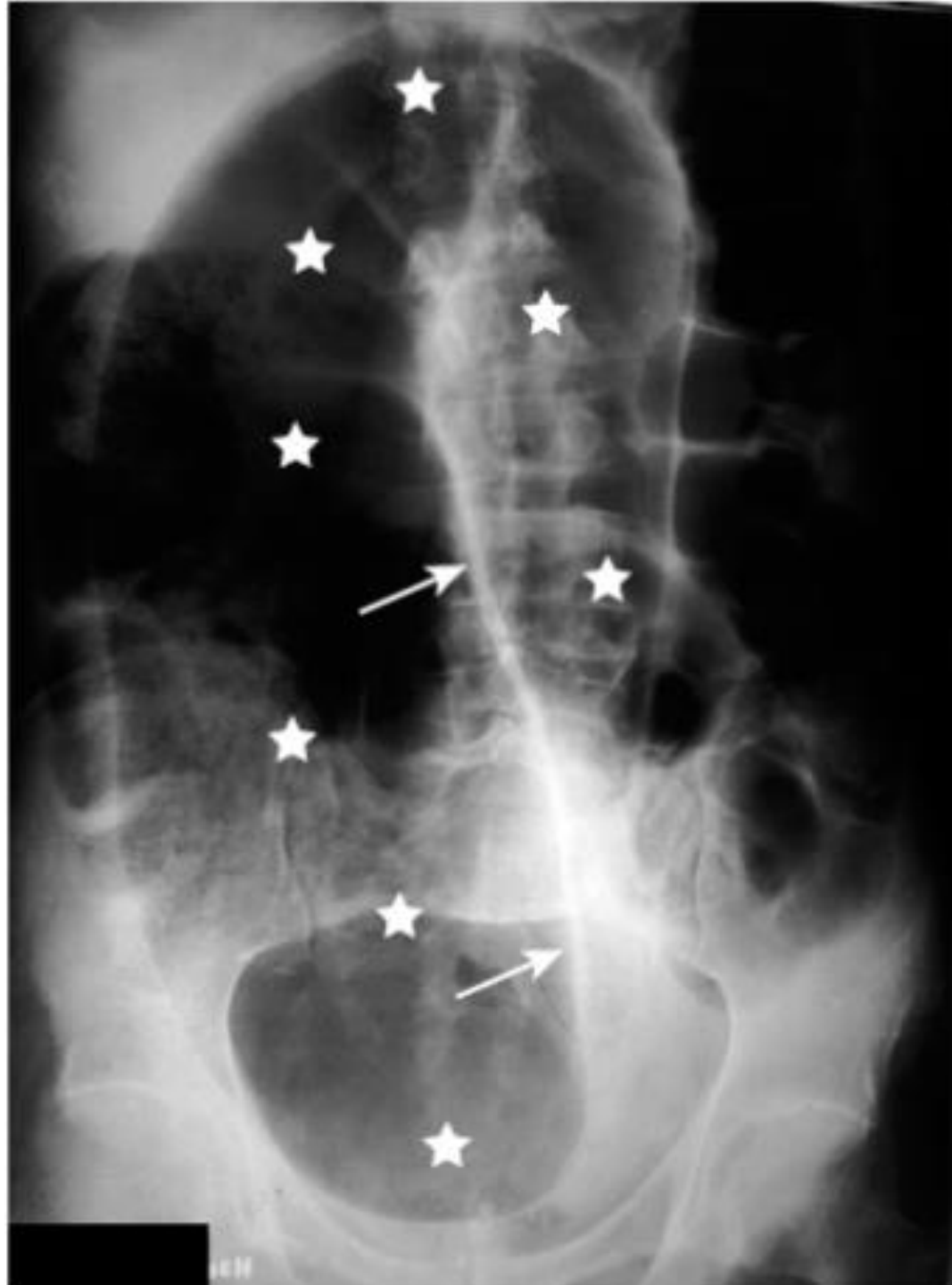


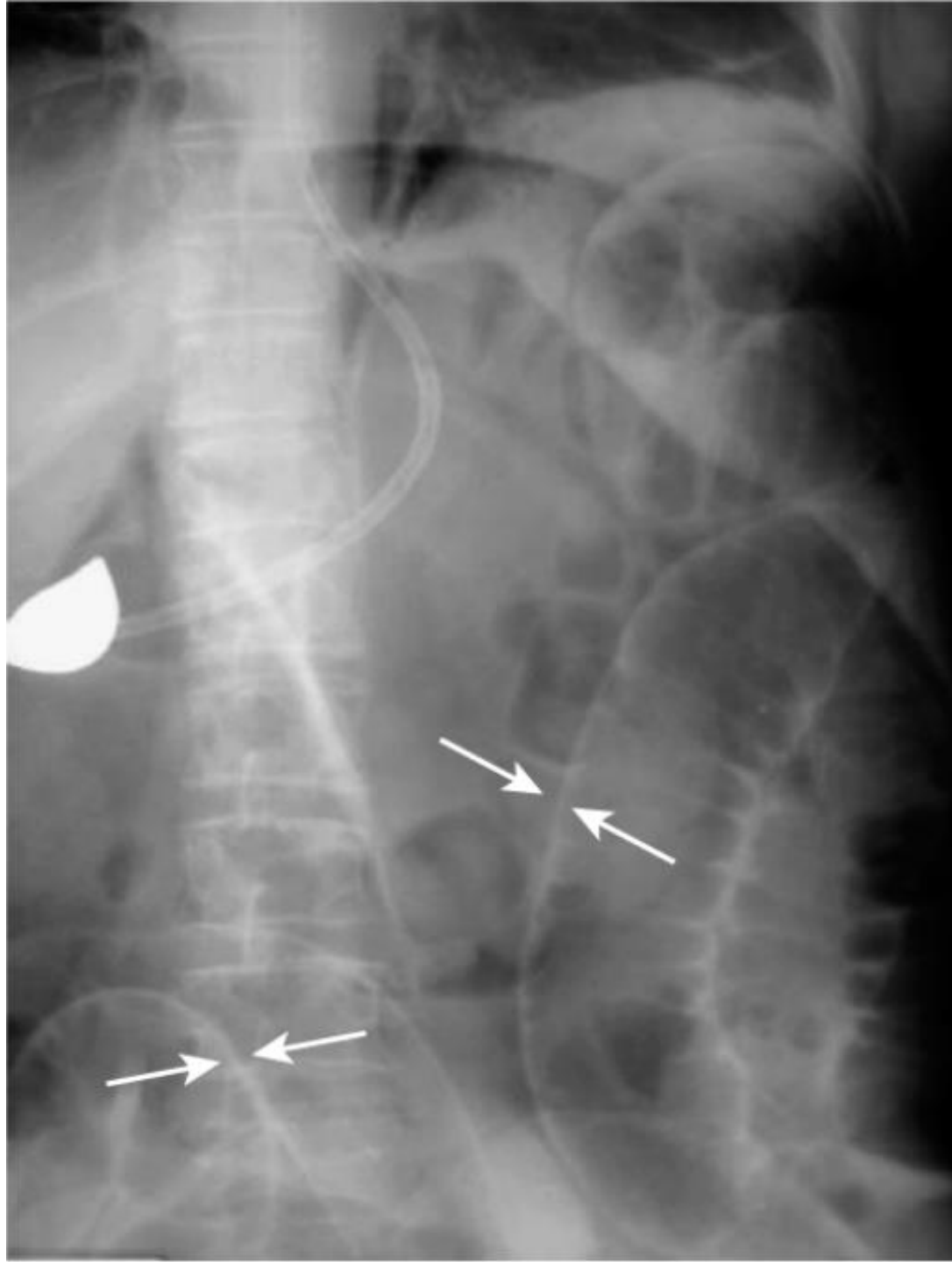
A

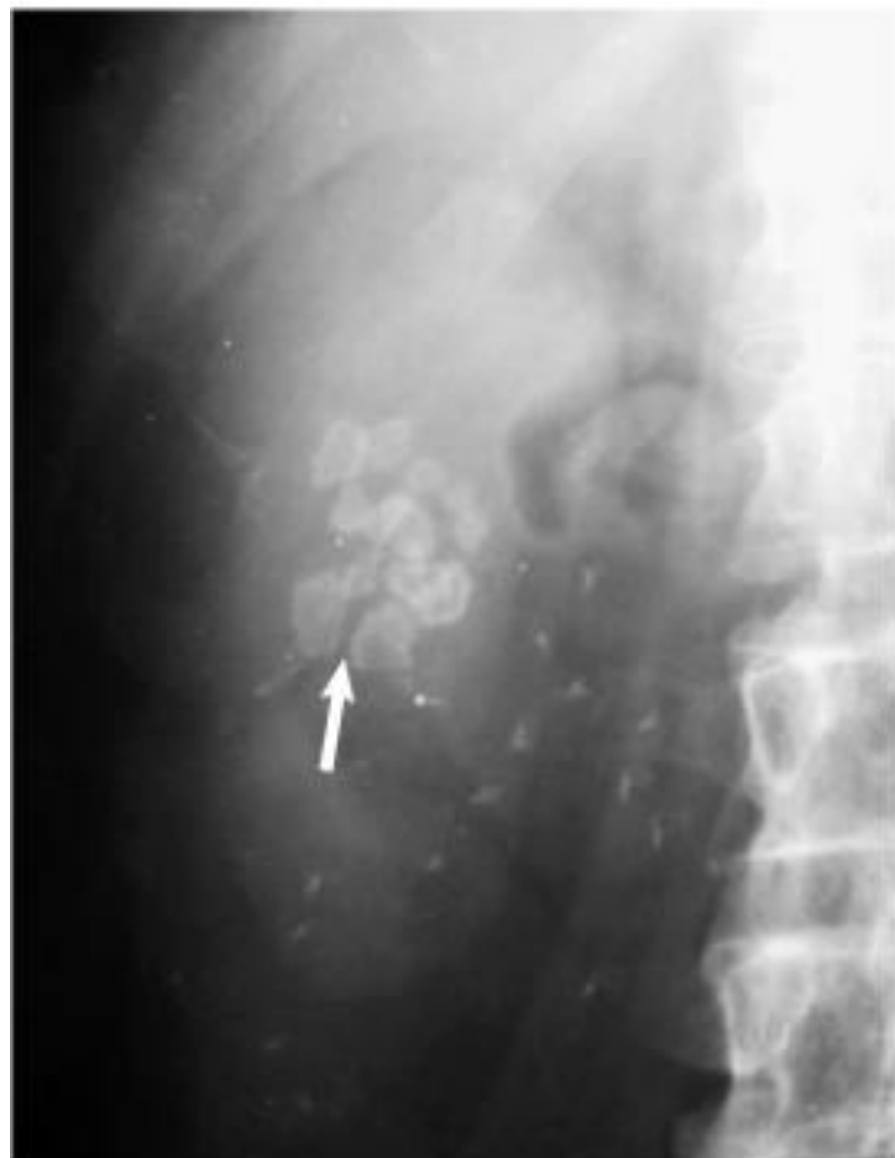

B

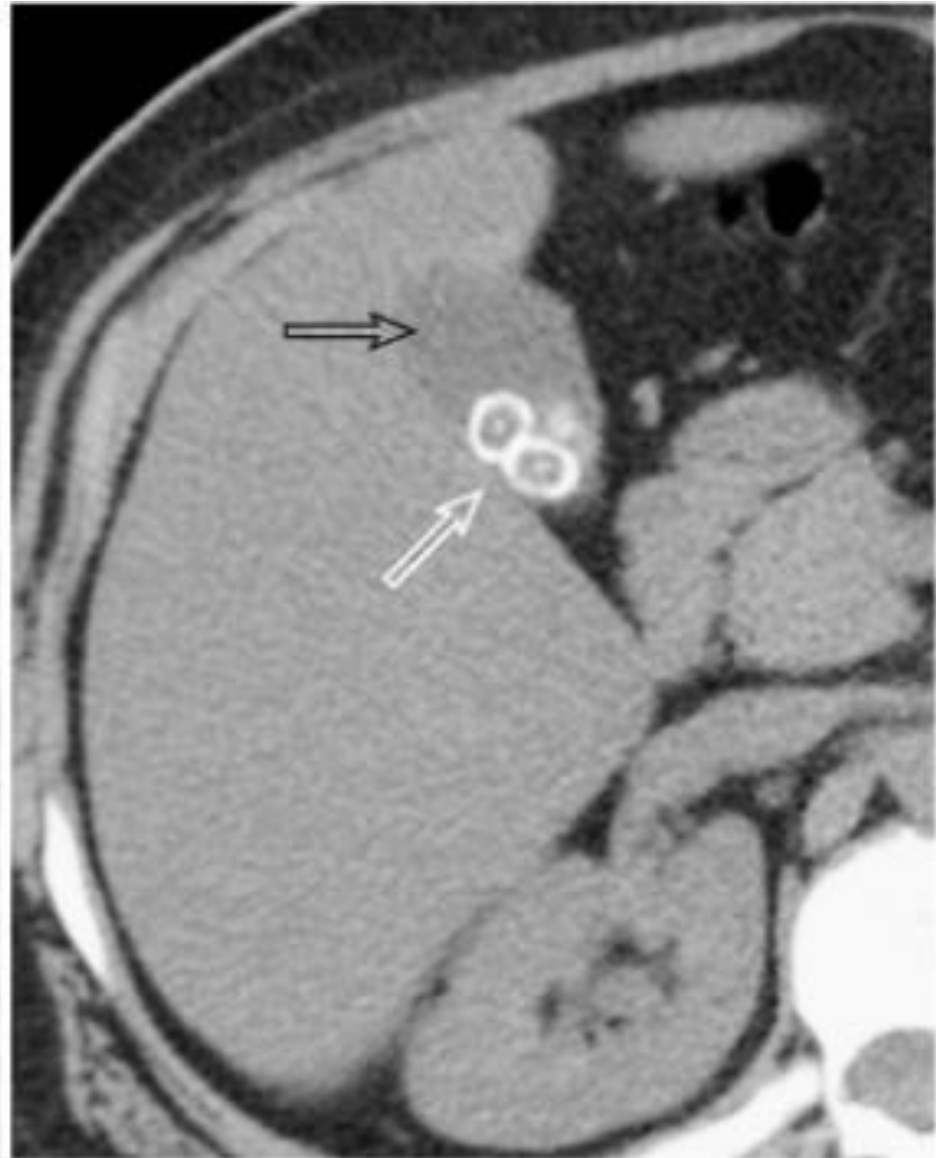





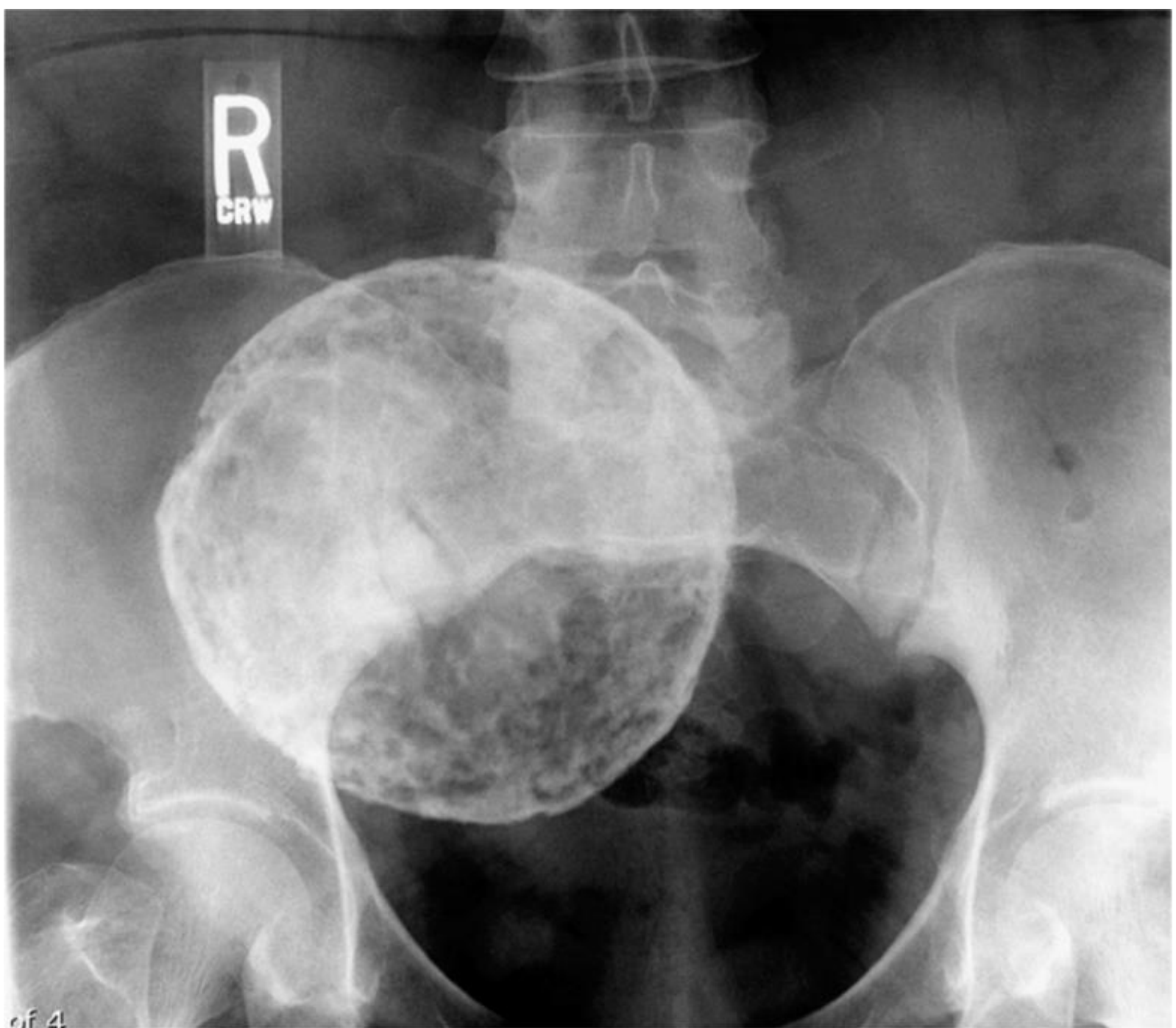


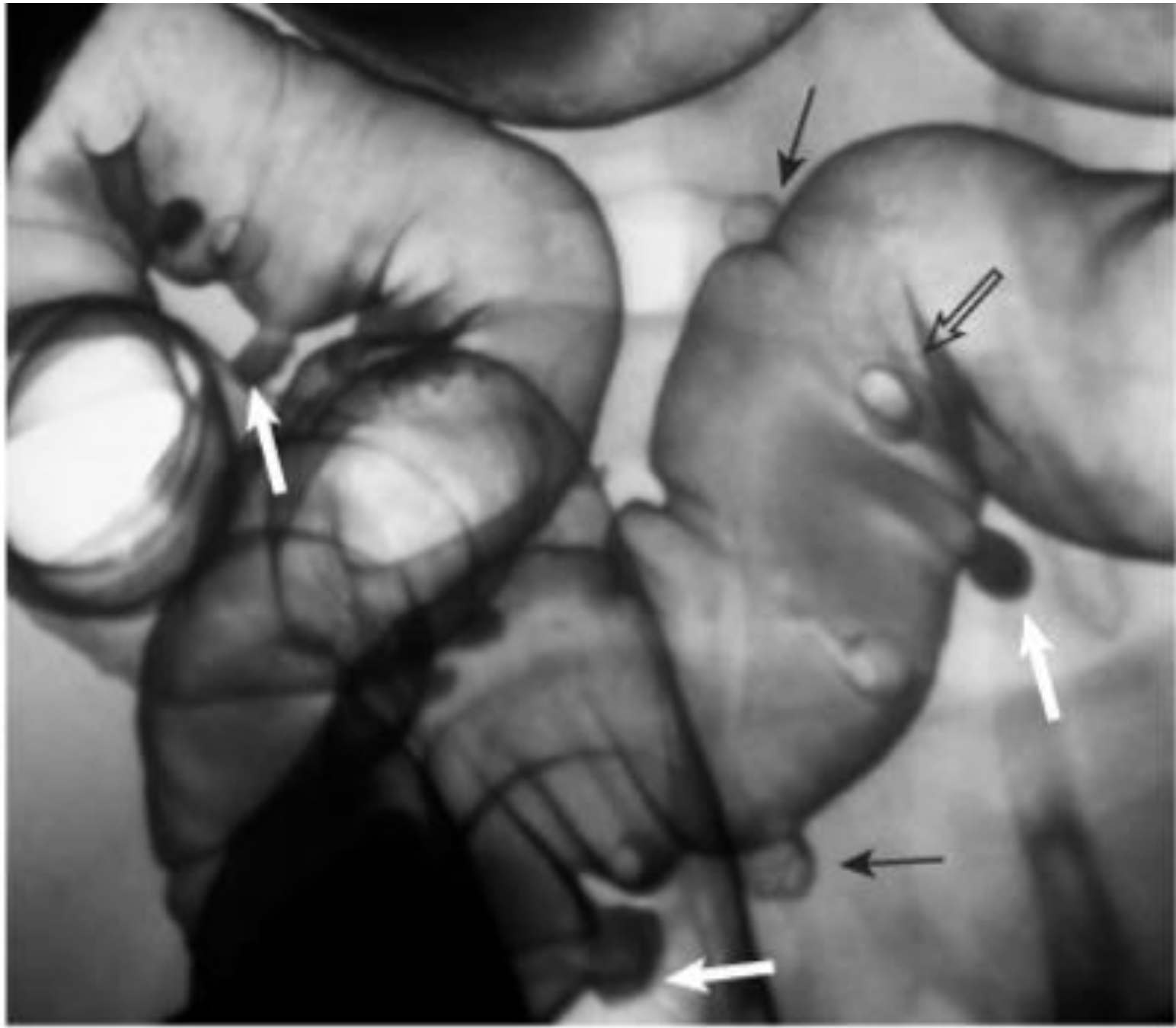
A



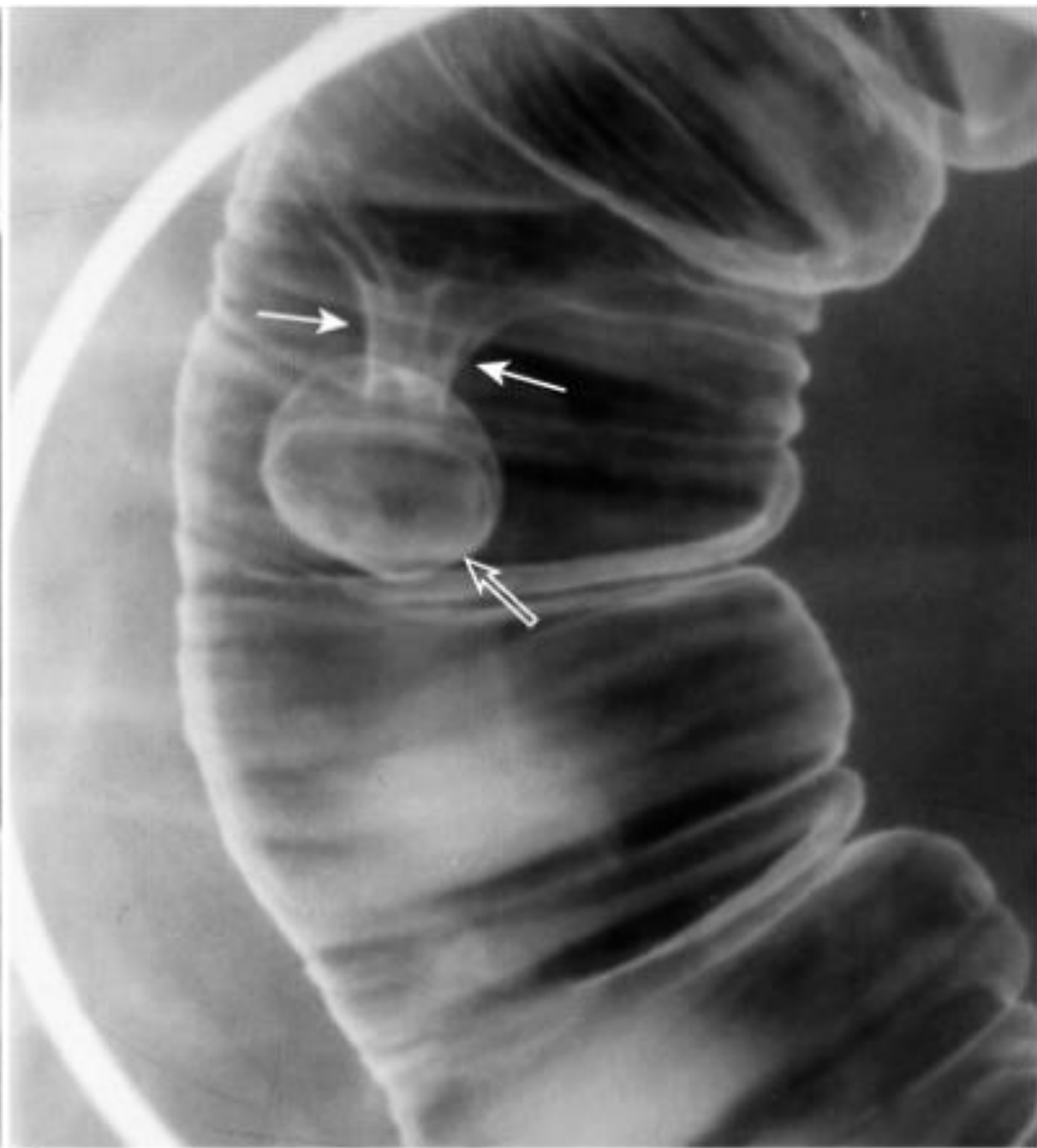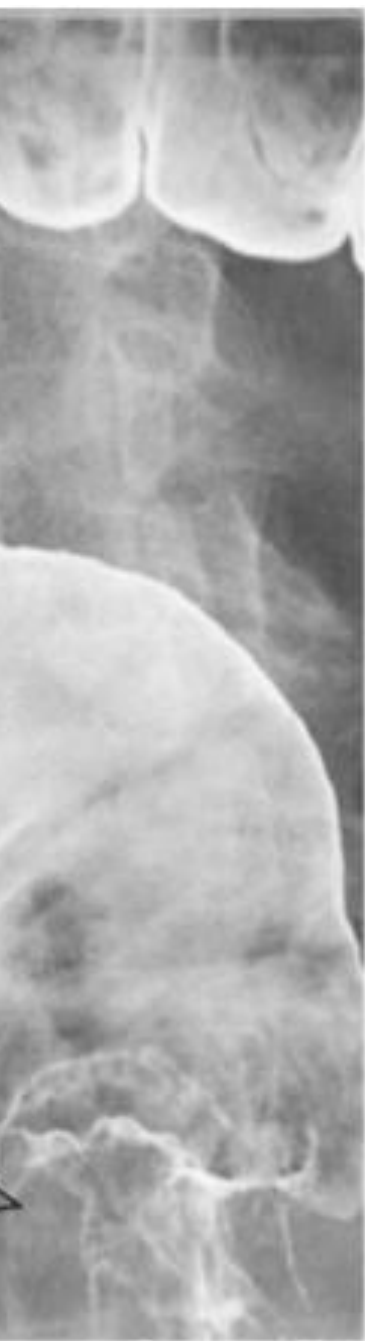B

C

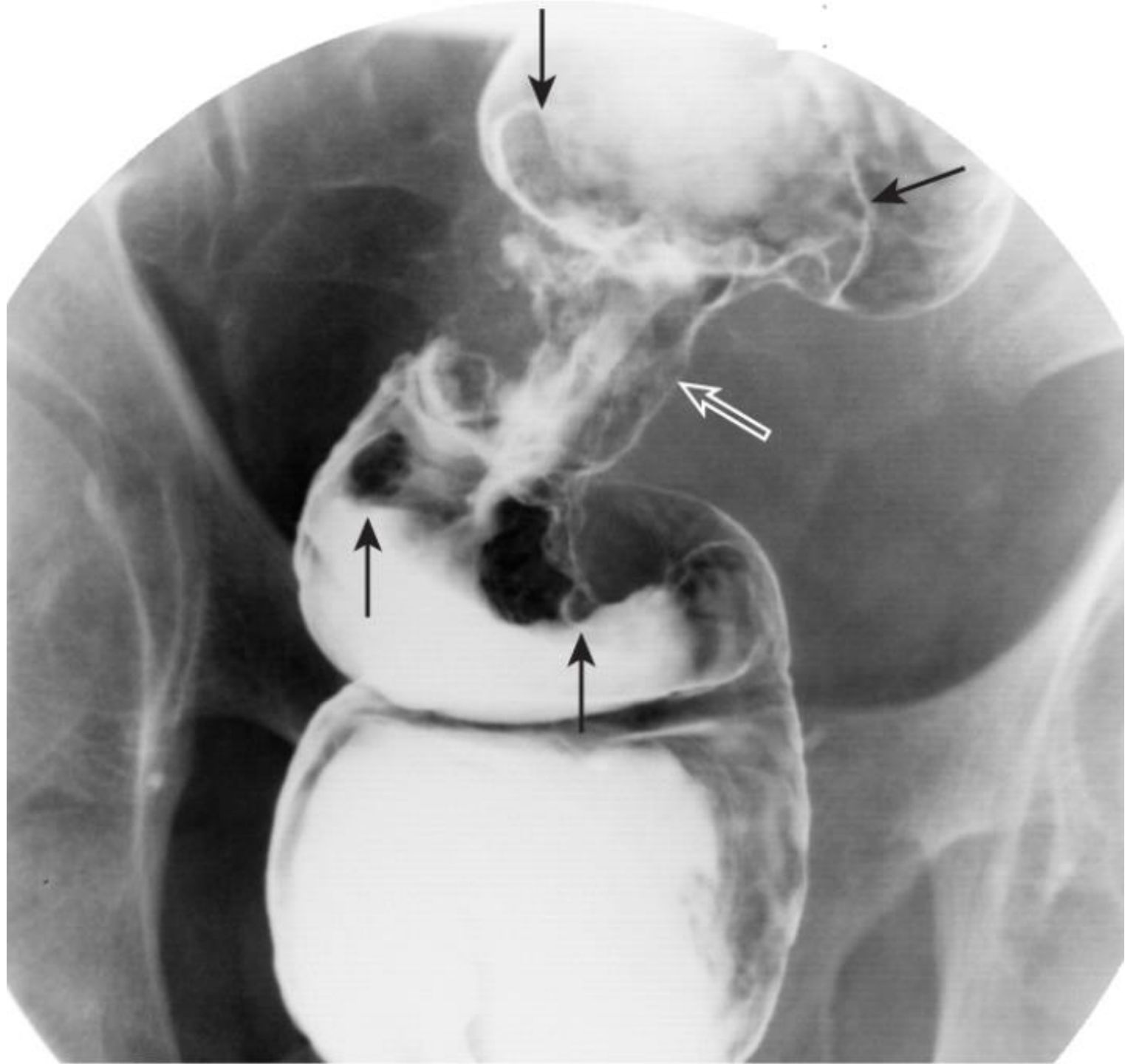




B



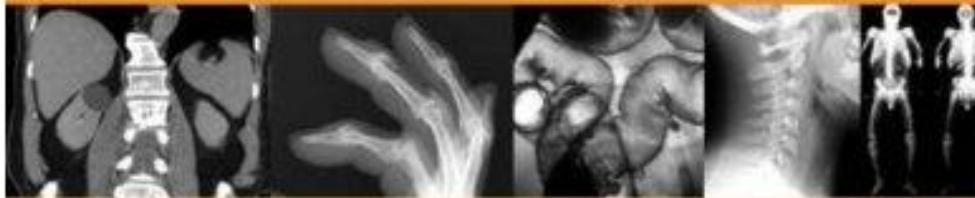B



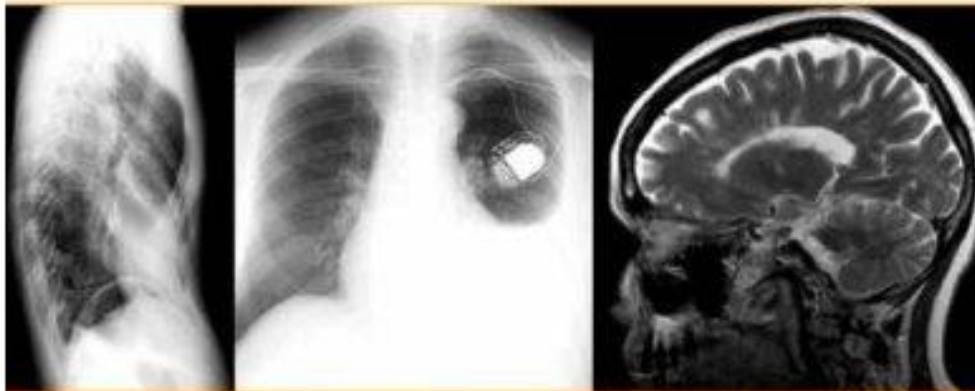


LEARNING RADIOLOGY

RECOGNIZING THE BASICS



William Herring, MD



MOSBY
an imprint of